



CONFRONTO DOSIMETRICO con SET UP in POSIZIONE SUPINA vs PRONA nella RADIOTERAPIA ADIUVANTE della MAMMELLA VOLUMINOSA e PENDULA: ANALISI RETROSPETTIVA della CASISTICA del MAURIZIANO

A. ROSSI, C. AIRALDI, D. NASSISI, E. GINO*, A. GIOSTRA*, A. RUGGIERI, M.G. RUO REDDA**

U.O.A. RADIOTERAPIA A.S.O. MAURIZIANO -TORINO

*U.O.A. FISICA SANITARIA A.S.O. MAURIZIANO -TORINO

** DIPARTIMENTO di ONCOLOGIA UNIVERSITA' di TORINO, A.O.U. S. LUIGI GONZAGA - ORBASSANO



Breast treatment planning

Prone breast irradiation for pendulous breasts

Jeroen Buijsen*, Jos J. Jager, Janneke Bovendeerd, Robert Voncken,
Jacques H. Borger, Liesbeth J. Boersma, Lars H.P. Murrer, Philippe Lambin

Department of Radiation Oncology (Mastro Clinic), GROW, University Hospital Maastricht, Maastricht, The Netherlands



Prone Whole-Breast Irradiation Using Three-Dimensional Conformal Radiotherapy in Women Undergoing Breast Conservation for Early Disease Yields High Rates of Excellent to Good Cosmetic Outcomes in Patients With Large and/or Pendulous Breasts

Carmen Bergom, M.D., Ph.D.,* Tracy Kelly, M.D.,* Natalya Morrow, Ph.D.,*
J. Frank Wilson, M.D.,* Alonzo Walker, M.D.,[†] Qun Xiang, M.S.,[‡]
Kwang Woo Ahn, Ph.D.,[‡] and Julia White, M.D.*

Departments of *Radiation Oncology and [†]Surgery and [‡]Division of Biostatistics, Medical College of Wisconsin, Milwaukee, WI

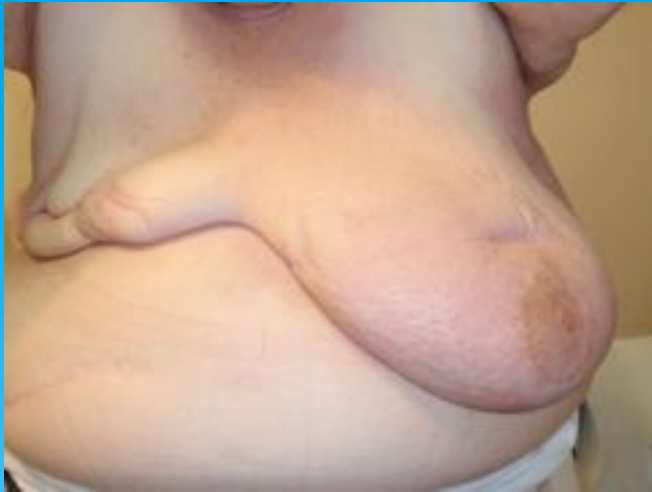

Clinical Investigation: Breast Cancer

Prospective Assessment of Optimal Individual Position (Prone Versus Supine) for Breast Radiotherapy: Volumetric and Dosimetric Correlations in 100 Patients

Stella C. Lymberis, M.D.,* John Keith deWynngaert, Ph.D.,* Preeti Parhar, M.D.,*
Arpit M. Chhabra, M.D.,* Maria Fenton-Kerimian, N.P.,* Jengwha Chang, Ph.D.,*
Tsvia Hochman, M.S.,^{1,†} Amber Guth, M.D.,[‡] Daniel Roses, M.D.,[§]
Judith D. Goldberg, Sc.D.,^{1,‡} and Silvia C. Formenti, M.D.*

*Department of Radiation Oncology, [†]Division of Biostatistics, [‡]Department of Environmental Medicine, and [§]Department of Surgery, New York University School of Medicine and Langone Medical Center, New York, New York

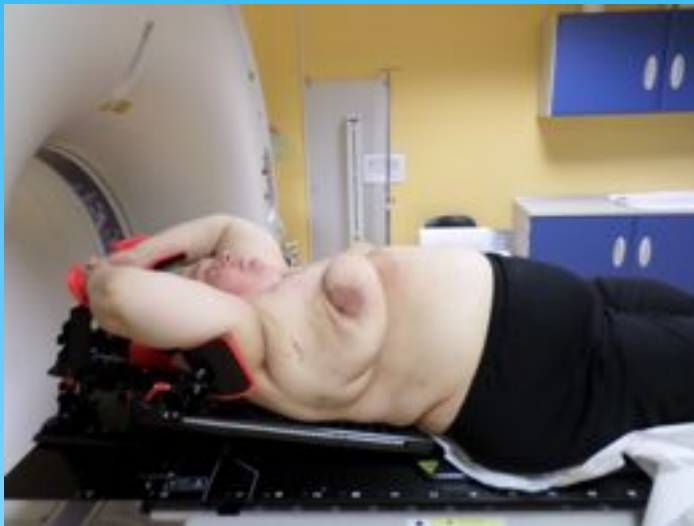

Limiti set up PoS:

- dislocazione mammaria laterale
- incremento piega inframammaria



- > disomogeneità copertura target
- > tox acuta (epidermiolisi umida)
- > dose OAR polmone e cuore

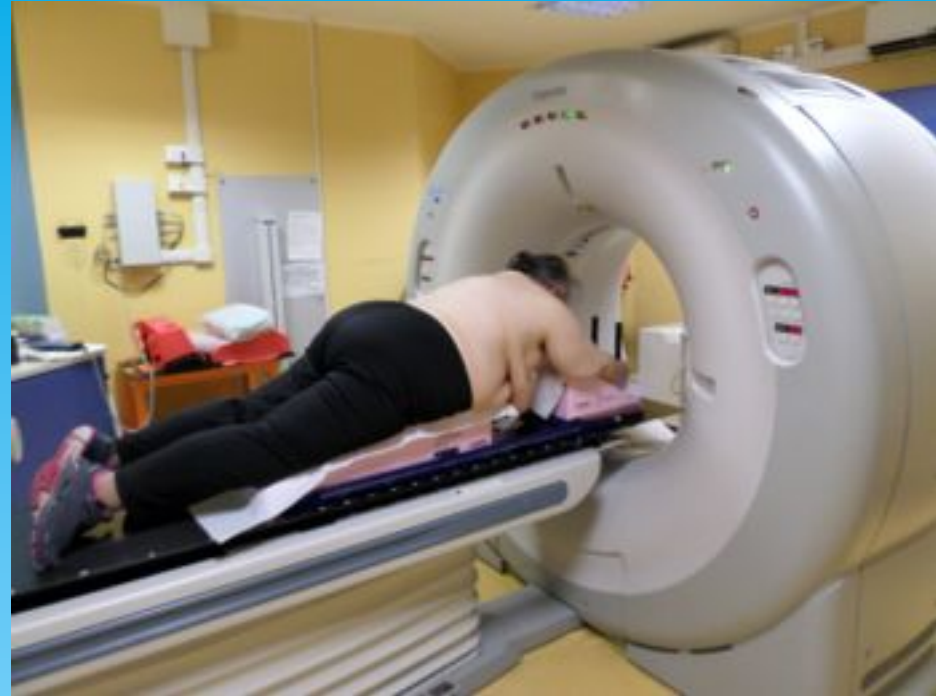

Vantaggi set up PoP:

- dislocazione mammaria anteriore con allontanamento dalla parete toracica
- riduzione escursione respiratoria



- > omogeneità copertura target
- < tox acuta (epidermiolisi umida)
- < dose OAR polmone (cuore)




Materiali e Metodi

Caratteristiche	N pazienti (11)
Età mediana (range)	60 (43-74)
BMI medio	>40
Stadio	
- IA	8
- IB	1
- IIA	1
- IIB	1
Quadrante	
- Q1	2
- Q1-2	2
- Q1-5	1
- Q2	3
- Q2-4	2
- Q3-5	1
Lato	
- Dx	5
- Sn	5
- Bilaterale	1
Istologia	
- CDI	11
TC prona/ supina	7



Giugno 2009

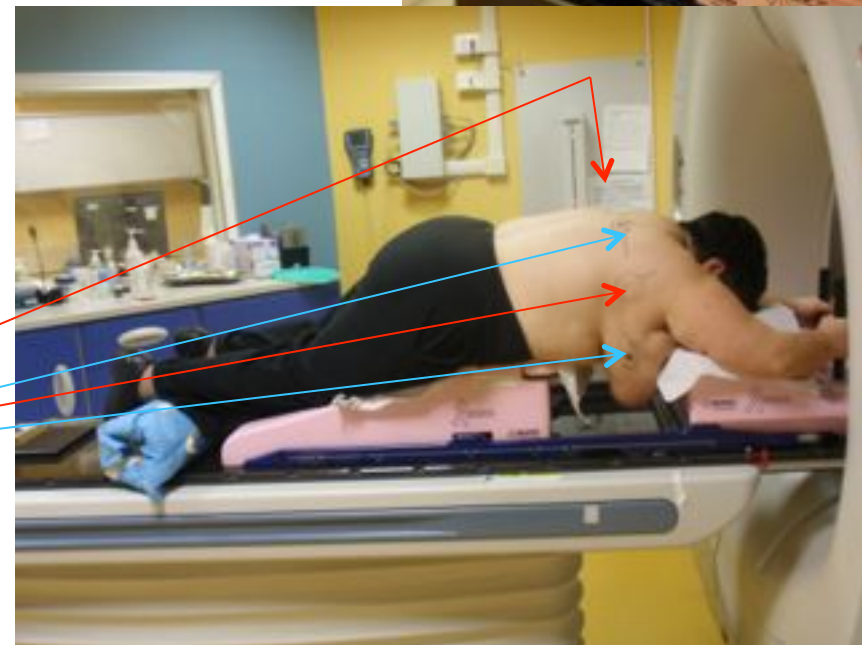
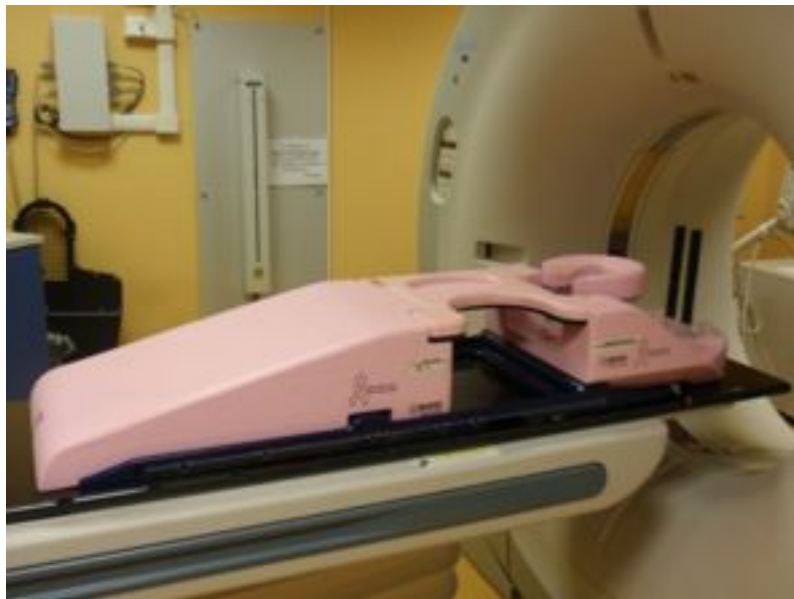

Ottobre 2014



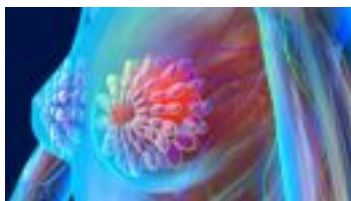

SET UP e TC simulazione

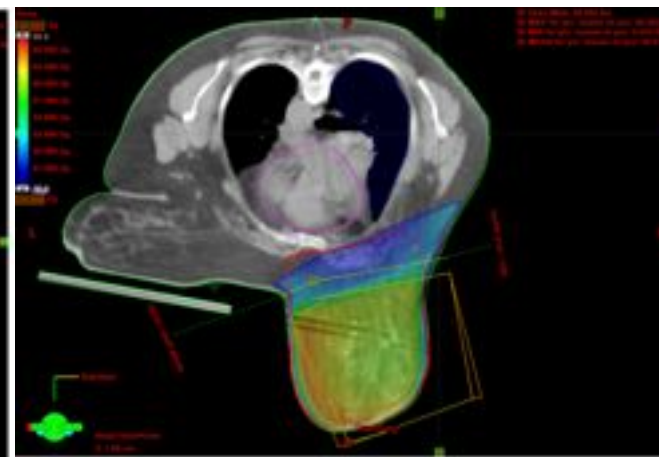
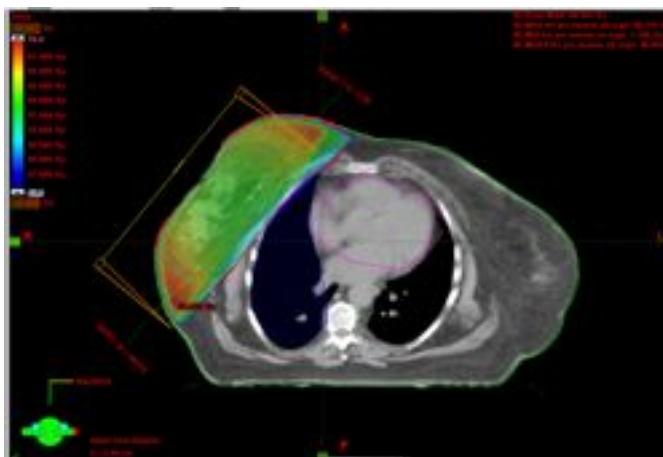


Tattoo

RISULTATI



PTV MAMMELLA	Supina (7 pazienti)	Prona (11 pazienti)
Volume medio (cc)	3250	3500
V95 (Gy)	85% (61-99)	88% (66-98)
V90 (Gy)	94% (88-100)	92% (88-95)

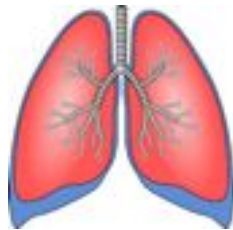

RISULTATI



OAR CUORE	Supina	Prona
V25 (Gy)	0	0
V10 (Gy)	0	0
V5 (Gy)	0	1,2
Dose media (Gy)	1,9	1,9

RISULTATI



OAR POLMONE	Supina	Prona
V20 (Gy)	13	3
V10 (Gy)	17	5
V5 (Gy)	24	7
Dose media (Gy)	7,7	2,5



CONCLUSIONI

- ✓ PoP possibile alternativa nelle pazienti con mammella voluminosa e pendula
- ✓ Copertura del target sovrapponibile al PoS
- ✓ Riduzione della dose OAR polmone
- ✓ Riduzione Tox acuta cutanea solco sottomammario
- ✓ Riproducibilità del set up funzione dell'agilità e compliance della paziente





Grazie

