



Associazione
Italiana
Radioterapia
Oncologica

LA RADIOTERAPIA
PALLIATIVA CON
TECNICHE SPECIALI
DELLA MALATTIA
METASTATICA

TERNI
21 giugno 2013



Radioterapia stereotassica body nel paziente oligometastatico

“The role of radiotherapy in the management of metastatic disease has been mainly limited to palliation, but we now have an opportunity to challenge this idea...”


Tree 2013

Mario Santarelli
UOC Radioterapia Rieti

Stereotactic body radiotherapy for oligometastases

Allison C Tree, Vincent S Khoq, Rosalind A Eeles, Merina Ahmed, David P Dearnaley, Maria A Hawkins, Robert A Huddart, Christopher M Nutting, Peter J Ostler, Nicholas J van As

La incidenza della **diffusione metastatica limitata** non è stata ben studiata ma svariati dati suggeriscono che sia nota e frequente specie per alcuni tipi di tumori:


- Polmone
 - Mammella
 - Colon-retto
 - Sarcomi
- 

Nuove tecniche di imaging

Il miglioramento delle tecniche di imaging e del loro appropriato uso evidenzia in percentuale sempre superiore la presenza di metastasi asintomatiche



Aumento della percentuale di evidenza di condizione di malattia oligometastatica



Barney JD, Churchill EJ: Adenocarcinoma of the kidney with metastasis to the lung cured by nephrectomy and lobectomy. J Urol 42:269-276, 1939

Caso di carcinoma renale con una metastasi
al polmone trattato con nefrectomia e lobectomia.
Il paziente muore dopo 23 anni senza recidiva
di malattia




Table 1. Summary of Surgical Metastasectomy and SBRT for Metastasis Therapy to Multiple Sites

Surgical Series	Year	No. of Patients	5-Year Survival (%)	10-Year Survival (%)	Site
Rees et al (colorectal cancer)	2008	929	36 ^a	23 ^a	Liver
Fong et al (colorectal cancer)	1999	1,001	37	22	Liver
Pawlik et al (colorectal cancer)	2005	557	58	No 10-year follow-up	Liver
Carpizo et al (colorectal cancer)	2009	1,369		No 10-year follow-up	
Liver only		1,242	49		Liver
Limited EHD		127	26		Liver and EHD ^b
De Haas et al (colorectal cancer)	2008				Liver
R0 resection		234	61	43	
R1 resection		202	57	37	
Elias et al (colorectal cancer)	1998	269	24.7	No 10-year follow-up	Liver
Elias et al (noncolorectal only)	1998	147	36	No 10-year follow-up	Liver
Scheele et al (colorectal cancer)	1995	350	39.3	23.6	Liver
de Jong et al (colorectal cancer)	2009	1,669	47.3	No 10-year follow-up	Liver
Pastorino et al (many primary tumors) ^c	1997	4,572	36	26	Lung
Choong et al (soft tissue sarcoma)	1995	274	40	No 10-year follow-up	Lung
Casiraghi et al (many primary tumors) ^d	2011	575	46	No 10-year follow-up	Lung
Pfannschmidt et al (renal cell carcinoma)	2002	191	39.6	No 10-year follow-up	Lung
Pfannschmidt et al (colorectal cancer)	2003	167	32.4	10-year follow-up	Lung
Kanemitsu et al (colorectal cancer)	2003	313	38.3	No 10-year follow-up	Lung
Petersen et al (melanoma)	2007			No 10-year follow-up	Lung
Complete resection		249	21		
Incomplete resection		69	13		
Saito et al (colorectal cancer)	2002	165	39.6	37.2	Lung
Kim et al (multiple primary tumors) ^e	1998	37	24	No 10-year follow-up	Adrenal
Porte et al (NSCLC)	2001	43	11 ^f	No 10-year follow-up	Adrenal
Mercier et al (NSCLC)	2005	23	23	No 10-year follow-up	Adrenal
Burt et al (NSCLC)	1992	185	13	7	Brain
Bonnette et al (NSCLC)	2001	103	11	No 10-year follow-up	Brain

serie chirurgiche hanno riportato ***favorevoli outcome clinici*** in pazienti con limitata estensione di malattia al fegato, polmone, surrenali e *cervello* ***evidenziando che una parte di pazienti con malattia limitata può essere curata con buone prospettive di risultato***


Outcomes after Resection of Synchronous or Metachronous Hepatic and Pulmonary Colorectal Metastases

2007

George Miller, MD, Peter Biernacki, BS, Nancy E Kemeny, MD, Mithat Gonen, PhD, Robert Downey, MD, FACS, William R Jarnagin, MD, FACS, Michael D'Angelica, MD, FACS, Yuman Fong, MD, FACS, Leslie H Blumgart, MD, FACS, Ronald P DeMatteo, MD, FACS

rates of 36% to 45%.⁹⁻¹² But the role of surgery in the management of patients who have both liver and lung metastases (either at the same or different times) is not well defined. In fact, development of both hepatic and pulmonary colorectal metastases is commonly regarded as an indicator of widespread tumor dissemination, and surgery is generally considered futile.

Unfortunately the benefits of resection and appropriate *selection criteria* in patients who develop metastasis are still poorly defined.




Radioterapia Stereotassica body

Perché SBRT ?

Motivo n° 1 un intervento radicale essere erogato durante una fase oligometastatica, potrebbe **modificare la progressione della malattia** nei pazienti che altrimenti sarebbero stati trattati palliativamente nella maggior parte dei casi

Motivo n° 2 Ritardare i successivi trattamenti

Motivo n° 3 La **corretta identificazione di un subset di pazienti oligometastatici** in cui la conseguente terapia ablativa consente **di modificare significativamente gli outcome clinici**



Radioterapia Stereotassica body

La SBRT di metastasi limitate ha mostrato promettenti tassi di **controllo locale** che vanno dal **65%** ed il **96%**

Le **OS a 2 o 3 anni** riportate nelle varie casistiche sono comprese tra il **30%** ed il **64%** risultate comparabili con i dati della chirurgia .

La SBRT:

- Meno invasiva
- Può essere applicata ad un più largo numero di tumori, organi e sedi
- Sedi meno accessibili alla chirurgia
- A pazienti unfit per la chirurgia
- Meno costosa

Milano MT et al Breast Cancer Res Treat 2009

Kang JK et al Clin Exp Metastasis 2010

Salama JK et al Cancer 2012

Bae SH et al J Surg Oncol 2012

Radioterapia Stereotassica body

Radiation Series	Year	No.		Local Control (%)	Survival (%)	Site
		Patients	Lesions			
Blomgren et al	1995	31	42	80	Not reported	Liver, lung, and retroperitoneum
Wulf et al	2004	41	51	80	33 ^a	Lung
Hoyer et al (colorectal cancer)	2006	64	141	86 ^a	38 ^a , 13 ^h	Lung, liver, and adrenal
Hof et al	2007	61	71	63 ⁱ	47.8 ⁱ	Lung
Rusthoven et al	2009	47	63	92 ^a	30 ^a	Liver
Rusthoven et al	2009	38	63	96 ^a	39 ^a	Lung
Kang et al (colorectal cancer)	2010	59	78	66 ⁱ	49 ^j	Multiple
Okunieff et al	2006	49	125	83 ⁱ	25 ^j	Lung
Katz et al	2007	69	174	57 ^k	24 ^{l,m}	Liver
Lee et al	2009	70	143	71 ^m	47 ⁿ	Liver
Milano et al	2011	121				Multiple ^p
Breast cancer		39		87 ^o	74 ^a , 47 ^o	
All others		82		65 ^o	39 ^a , 9 ^o	
Salama et al	2011	61	111	66.7 ^{a,q}	56.7 ^a	Multiple
Bae et al (colorectal cancer)	2012	41	50	64 ⁱ , 57 ^h	64 ⁱ , 38 ^h	Lung, liver, and lymph node
Norihisa et al	2008	34		90 ^a	84.3 ^a	Lung

Studi retrospettivi

Radioterapia Stereotassica body

Table 2. Selected Ongoing Prospective Trials for Oligometastases

Trial Name or Number	Design	Eligibility	Intervention
SABR-COMET	Randomized	All metastatic sites treatable; maximum of three tumors to any single organ system; controlled primary tumor	Standard arm: palliative-scheme radiation; experimental arm: stereotactic ablative radiation
UPCI 10-028	Phase II	≤ Five metastases from solid malignancy	SBRT to affected sites
UPCI 10-027	Phase II	≤ Five metastases diagnosed at initial presentation	SBRT to affected sites in combination with treatment of primary tumor
NCT01565837	Phase II	Melanoma with ≤ five metastatic sites (not resectable)	Ipilimumab with SBRT to all sites, timed to be delivered before third cycle
NCT01185639	Phase II	NSCLC with ≤ five metastatic sites, involving lung, liver, adrenal, or spinal lesions; if primary untreated, must have ≤ three	SBRT to affected sites, delivered in three or five fractions
PulMiCC	Randomized	Pulmonary metastases from colorectal cancer	Standard: active monitoring; experimental: active monitoring with pulmonary metastasectomy


Abbreviations: NSCLC, non-small-cell lung cancer; PulMiCC, Pulmonary Metastasectomy in Colorectal Cancer; SABR-COMET, Stereotactic Ablative Radiotherapy for Comprehensive Treatment of Oligometastatic Tumors; SBRT, stereotactic body radiotherapy; UPCI, University of Pittsburgh Cancer Institute.

Studi prospettici in corso

Stereotactic Ablative Radiotherapy for Comprehensive Treatment of Oligometastatic Tumors (SABR-COMET).

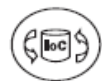Radiosurgery for Patients Recurrent Oligometastatic Disease. Radiosurgery for Patients With Oligometastatic Disease at Initial Presentation.

Concurrent Ipilimumab and Stereotactic Ablative Radiation Therapy (SART) for Oligometastatic But Unresectable Melanoma. <http://clinicaltrials.gov/>

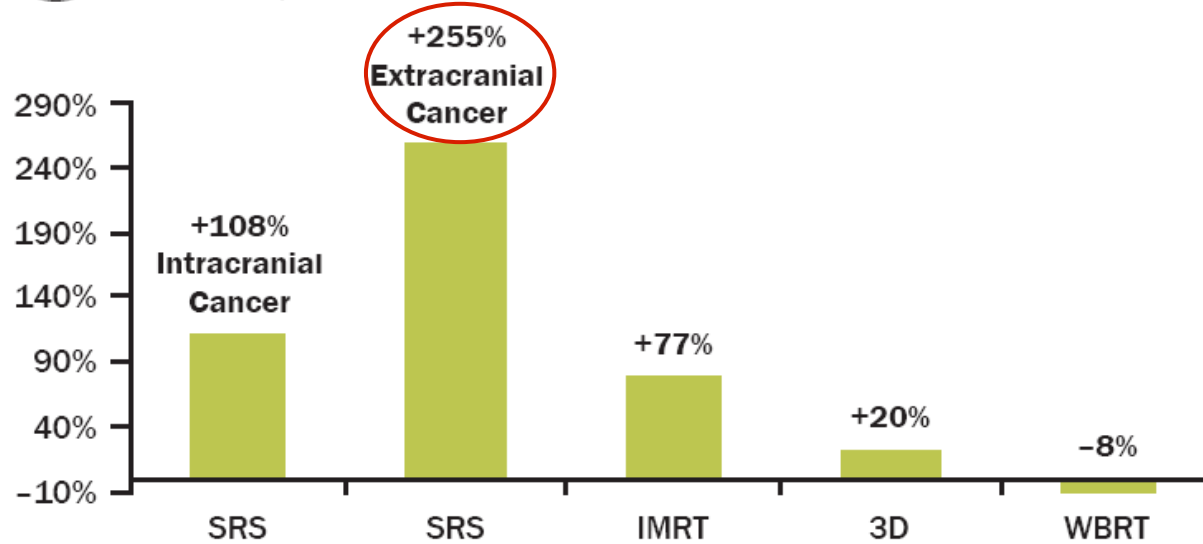


Radiosurgery is growing for the treatment of non-neurological tumors.

- Breast
- Liver
- Lung
- Pancreas
- Prostate
- Rectum
- Spine

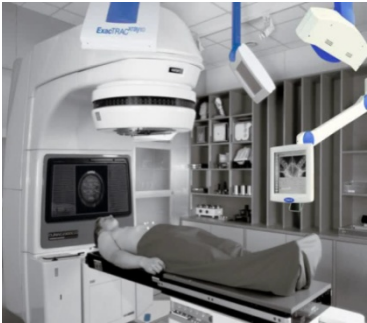

**10-Year Growth Forecast
US Market, 2006-2016**



Data from "US Clinical Intelligence Report 2007"

SBRT Linac-based



Trilogy




Vero



Cyberknife




Tomotherapy



SBRT: LINAC dedicato o modificato?

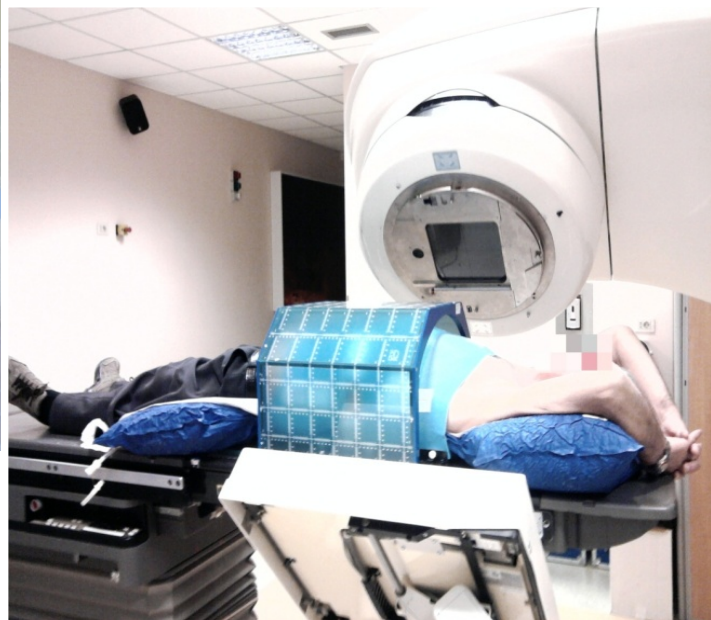
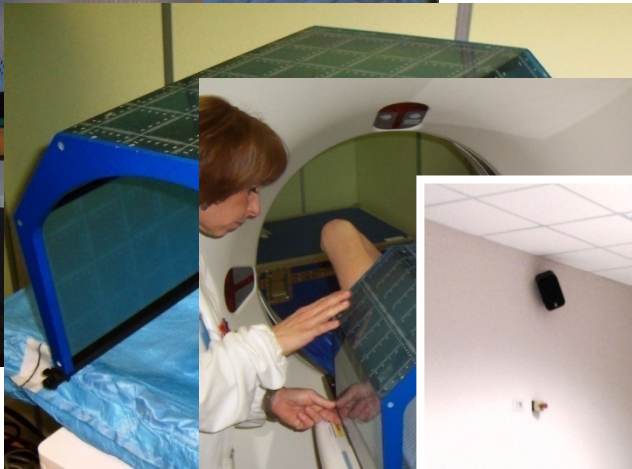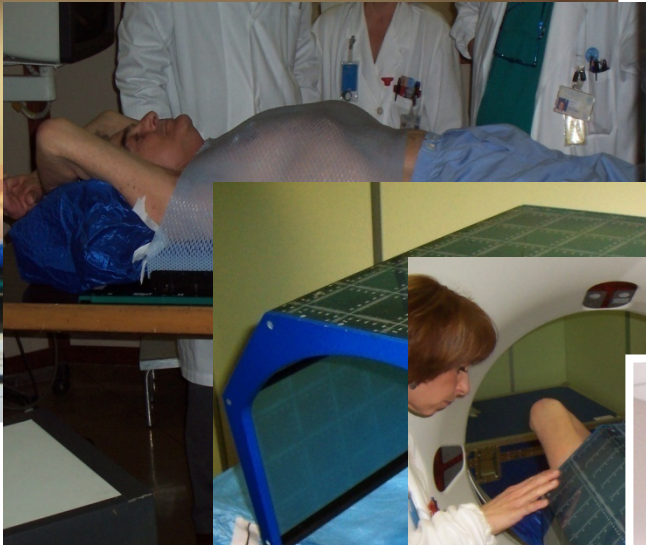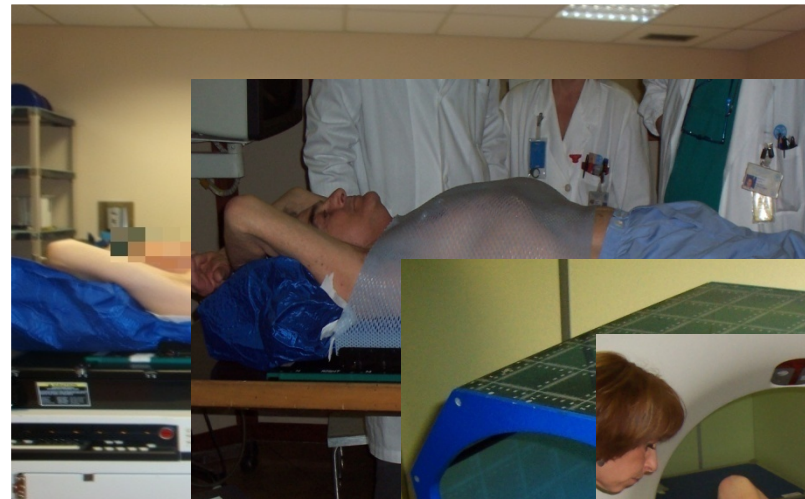- ▶ Aumenta le applicazioni del LINAC con maggiore focalizzazione e precisione spaziale



Radioterapia Stereotassica body

Progressi dell'approccio tecnico

- ✓ Miglioramento della fase diagnostica di identificazione dei contorni della lesione e di una più corretta pianificazione
- ✓ adeguata immobilizzazione e riposizionamento del paziente
- ✓ corretta collocazione del volume da trattare nei 3 assi dello spazio (fiducials, body-frame, riflettori optoelettronici, OBI , cone beam CT etc.)
- ✓ adeguato controllo della organ motion respiratoria per la massima riduzione dei margini interni.



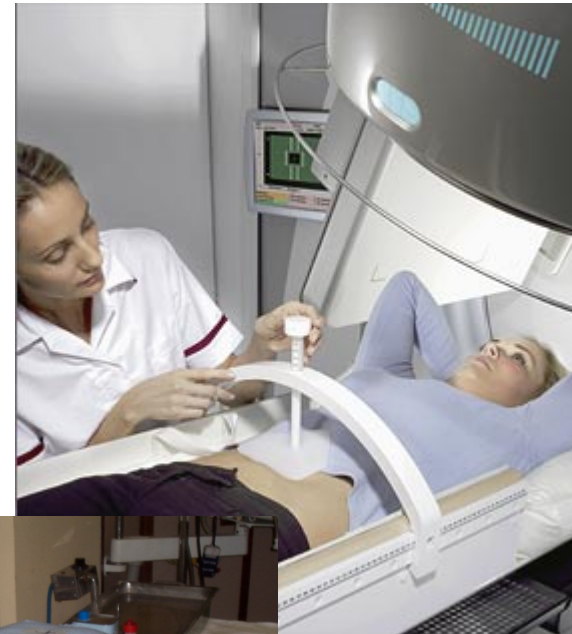
Controllo del Respiratory Motion

Dampening or inhibitory techniques

La **compressione addominale obbliga il paziente ad usare solo la gabbia toracica per respirare**, con conseguente riduzione del movimento complessivo intratoracico

Vantaggi: semplice, nessuna pausa nell'erogazione della RT, non necessita di particolari tecnologie, è la tecnica più usata

Svantaggi: discomfort per il pz., non estremamente preciso (escursioni del target anche di 0.5-1 cm)


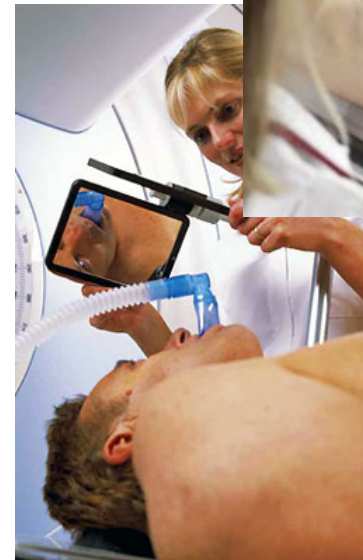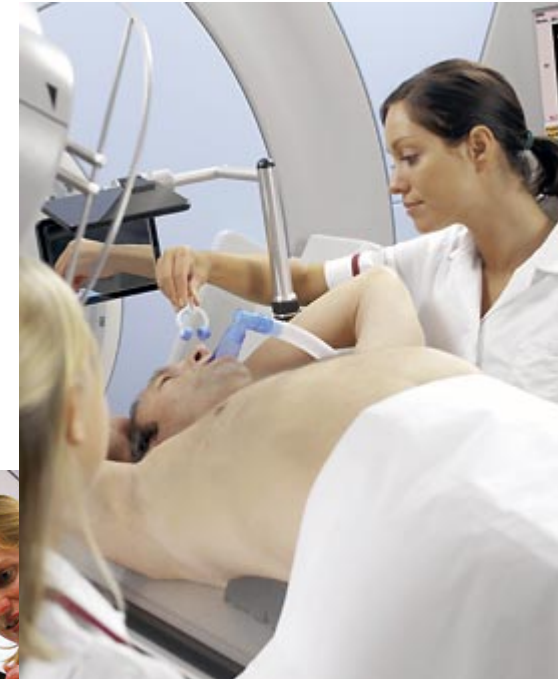



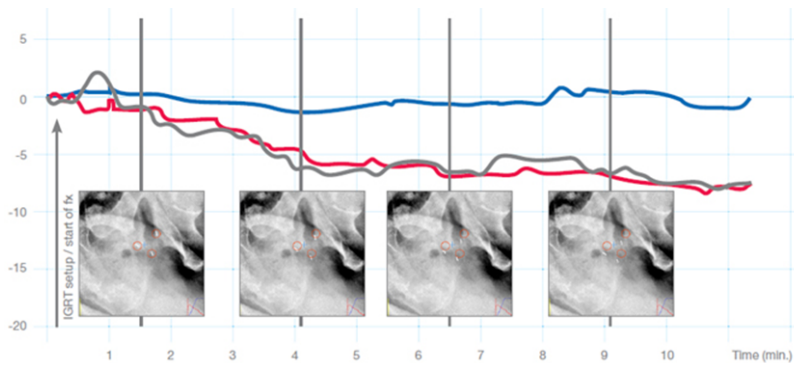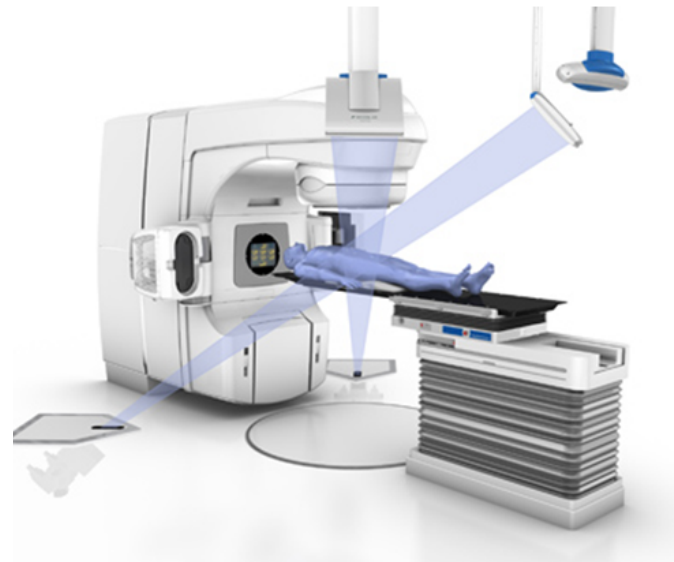
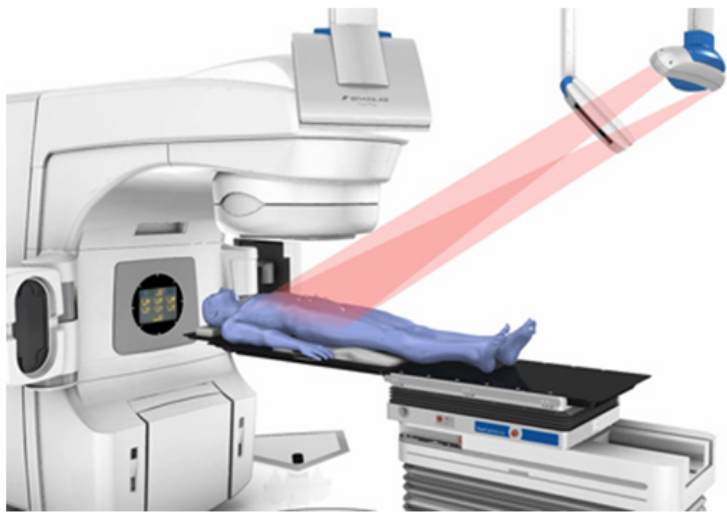
Controllo del Respiratory Motion

L' **active breath control (ABC)**,

è un' altra forma di ***inibizione del respiro, ma controllata dal pz. stesso***. Il trattamento viene erogato solo durante alcune fasi del respiro del paziente (ispirazione, fase del respiro in cui il polmone è più stirato e quindi il tessuto sano è più lontano)

Svantaggi: training del paziente, allungamento dei tempi di RT





Riposizionamento automatico

Controllo del Respiratory Motion

Gating systems

➤ La macchina seguendo il ciclo respiratorio del paziente, eroga RT in genere **in espirazione** (fase più lunga del ciclo), e si ferma quando il pz. inspira.

Vantaggi: maggiore compliance e confort per il pz.

Svantaggi: allungamento dei tempi, maggior rischio di tox per tessuti sani (< stiramento polmone con < distanza tumore/tessuti sani).



Beam Off




Beam On



Beam On



Beam Off



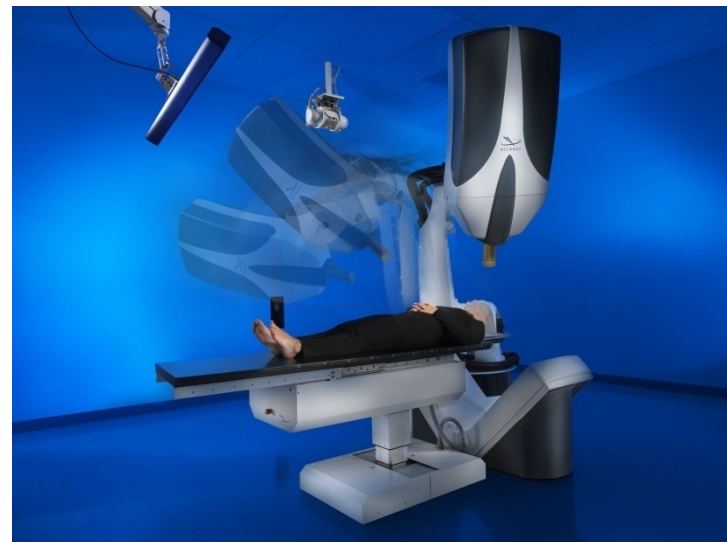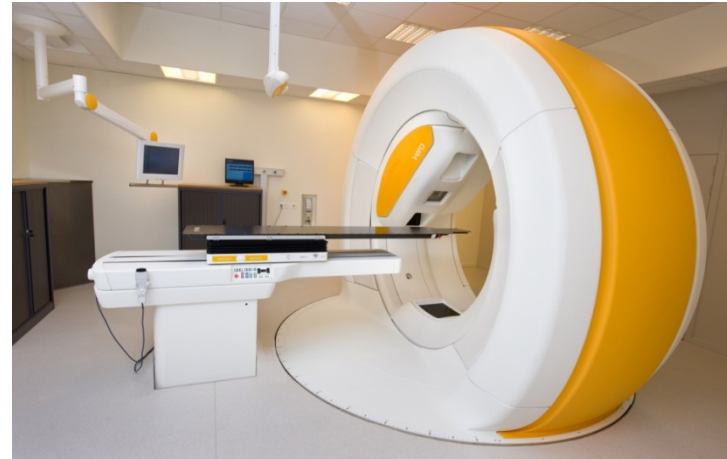Controllo del Respiratory Motion

Tracking systems

Prevedono la possibilità che il fascio possa seguire continuamente il target nel suo movimento, ad esempio come fa **cyberknife** o **Vero** , o attraverso un **collimatore dinamico** che modifica continuamente la posizione delle lamelle.

Vantaggi: erogazione continua di RT

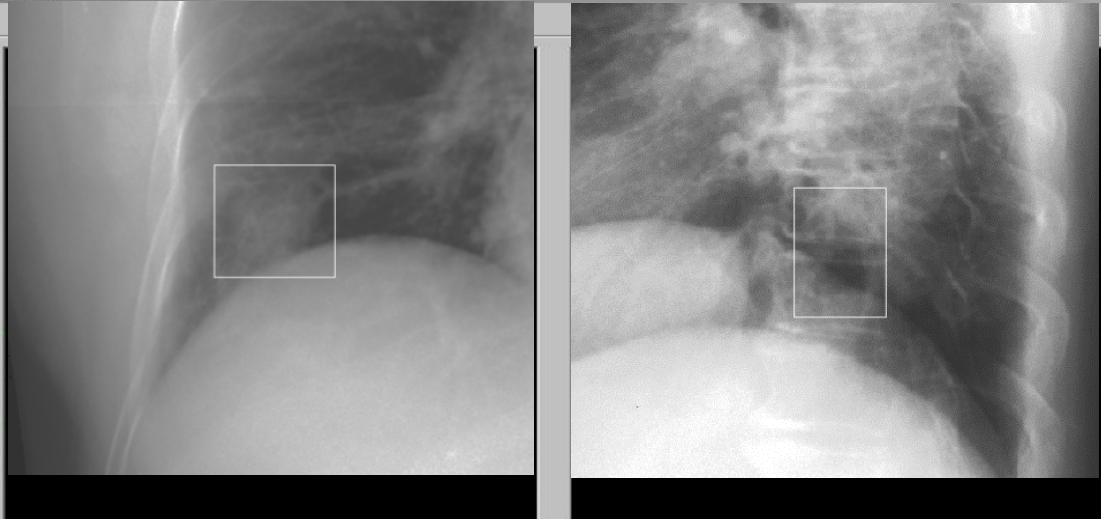
Svantaggi: rischio di movimenti incontrollati e di “ritardi” della macchina nel seguire il target.



DYNAMIC TUMOR TRACKING

ExacTrac Vero 3.0.0 BETA 2010 © Copyright BrainLAB AG Test_ETX_Phantom

Model Check



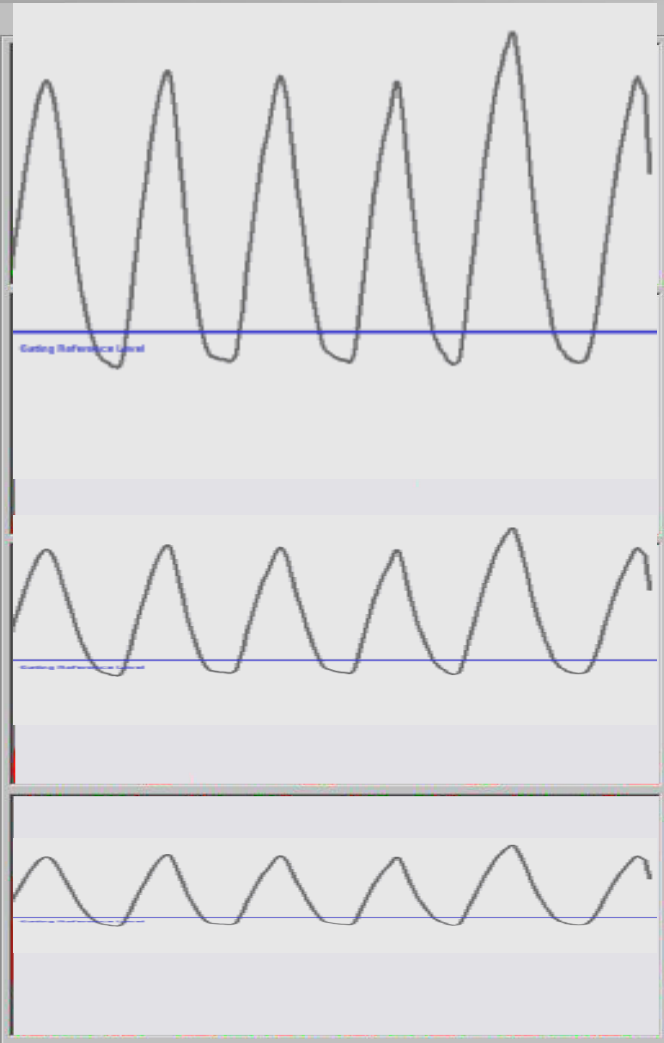
Contours

Motion and Correlation Results

	Mean Difference [mm]	Standard Deviation [mm]	Peak to Peak Target Motion [mm]
Lateral	n/a	n/a	n/a
Cranio Caudal	n/a	n/a	n/a
Superior Inferior	n/a	n/a	n/a

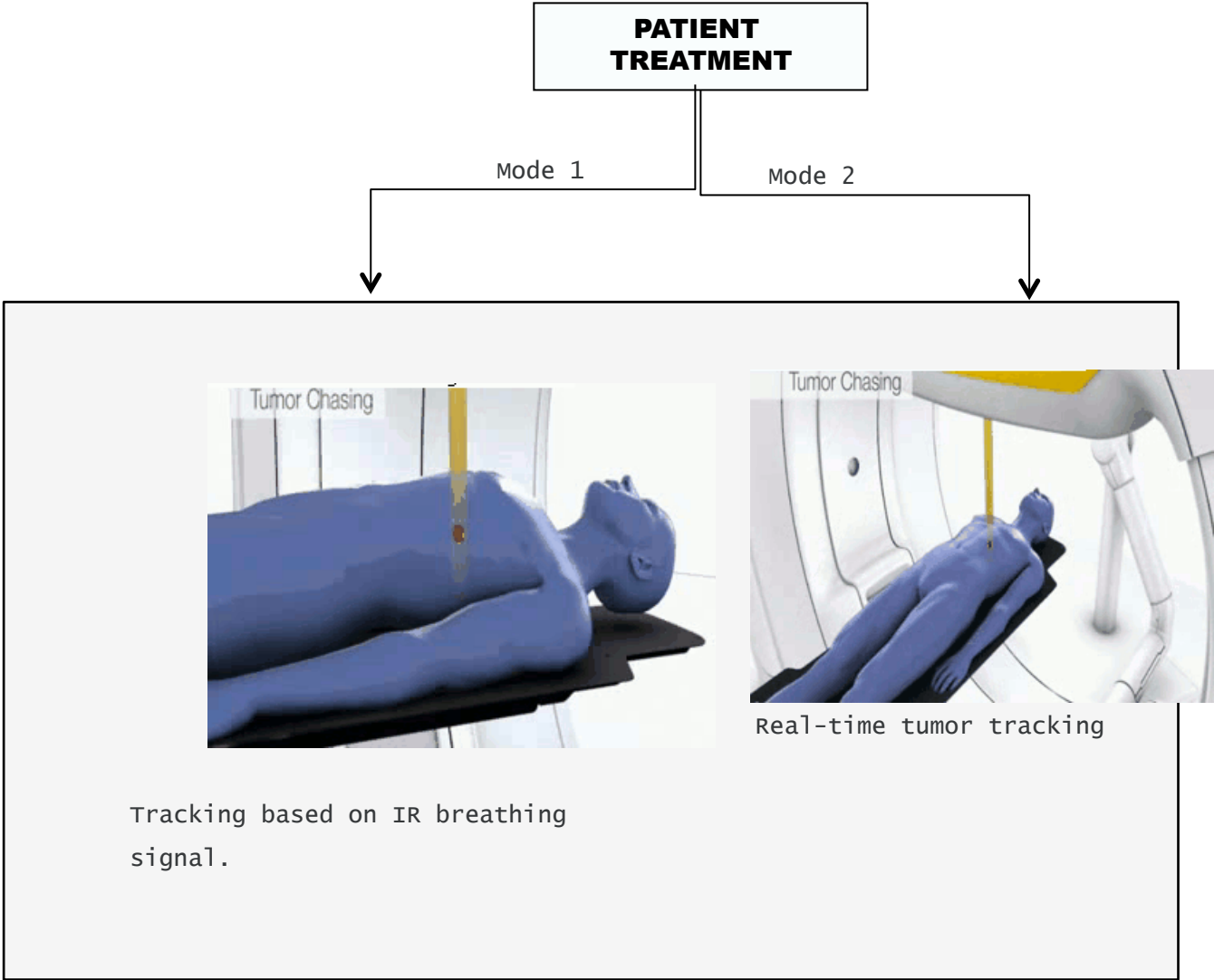
Comments from TPS

Output to ExacTrac: Approved: kunio 2008/07/14 16:49:38 Plan: ConformalBeam1 Exported: iPlan RT Dose 3.0.2



Check the accuracy of the automatic tumor detection algorithm and the correctness of the correlation model.


DYNAMIC TUMOR TRACKING



Radioterapia Stereotassica body

Fattori che influenzano il controllo locale ,PFS ed OS

Tossicità dei trattamenti



SRBT : Fattori che influenzano il controllo locale ,PFS ed OS

1) Numero delle metastasi

1 a 3 metastasi	9 mesi	Miglior PFS	46% ulteriore diffusione metastatica
4 o 5 metastasi		Peggior PFS	75% ulteriore diffusione metastatica

Salama et al Cancer 2011

[Cancer](#). 2012 Jun 1;118(11):2962-70. doi: 10.1002/cncr.26611. Epub 2011 Oct 21.

Stereotactic body radiotherapy for multisite extracranial oligometastases: final report of a dose escalation trial in patients with 1 to 5 sites of metastatic disease.

Salama JK, Hasselle MD, Chmura SJ, Malik R, Mehta N, Yenice KM, Villaflor VM, Stadler WM, Hoffman PC, Cohen EE, Connell PP, Haraf DJ, Vokes EE, Hellman S, Weichselbaum RR.

2) Istologia

Breast cancer

PFS a 2 aa	36% vs 13%	altri tumori
OS a 6 aa	49% vs 9%	altri tumori
LC a	87% vs 74%	altri tumori

Milano et al IJROBP 2012

882 Milano et al.

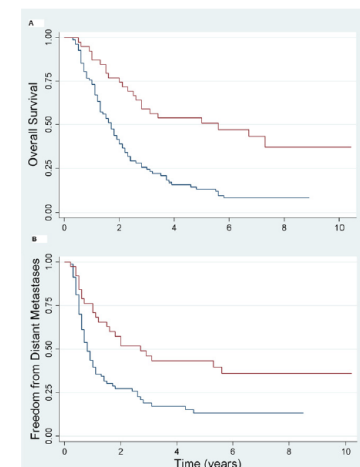


Fig. 1. Kaplan-Meier actuarial (A) overall survival and (B) freedom from distant progression for breast cancer (red line) and nonbreast cancer (blue line) patients. A color version of this figure is available at www.redjournals.com.

SRBT : Fattori che influenzano il controllo locale ,PFS ed OS

3) Sede

Una revisione retrospettiva di pazienti con **metastasi confinata a un organo** ha dimostrato che quelle **ossee** o **linfonodali toraciche** hanno una migliore sopravvivenza di quelle polmonari o epatiche, e che tendono anche ad avere una migliore sopravvivenza libera da progressione.

Milano MT et al AJCO 2010

➤ **La sede più o meno critica della metastasi** condiziona a volte il risultato terapeutico condizionando la possibilità di erogare dosi elevate

4) Disease-free interval

Se tempo della recidiva	> 12 mesi	OS a 3 aa	53%
	< 12 mesi	OS	19%

Inoue et al Jpns JCO 2010

Se DFS > 12 mesi OS superiore HR 0.51, 95%

Zhang et al Chin Med J 2011



SRBT : Fattori che influenzano il controllo locale ,PFS ed OS

5) Diametro

Il diametro della metastasi è predittivo del controllo “ in field “

Choi et al IJROBP 2009

Il controllo in field è inversamente proporzionale al diametro della metastasi

Milano et al IJROBP 2012

Metastasi epatiche

< 3 cm controllo del 100% a 2 anni


➤ 3 cm controllo del 77%

Rusthoven et al JCO 2009

6) Dose e Volumi di contornazione

Diversi Modelli investigativi

Dosi e frazioni differenti per organi ed apparati differenti



SRBT : Fattori che influenzano il controllo locale ,PFS ed OS

5) Diametro

Il diametro della metastasi è predittivo del controllo “ in field “

Choi et al IJROBP

2009

Il controllo in field è inversamente proporzionale al diametro della metastasi

Milano et al IJROBP 2012

Metastasi epatiche

< 3 cm controllo del 100% a 2 anni


> 3 cm controllo del 77%

Rusthoven et al JCO

2009

6) Dose e Volumi, metodi di contornazione e finalità

Il CTV della SBRT è in genere diverso (minore) rispetto alla 3D-CRT




Finalità

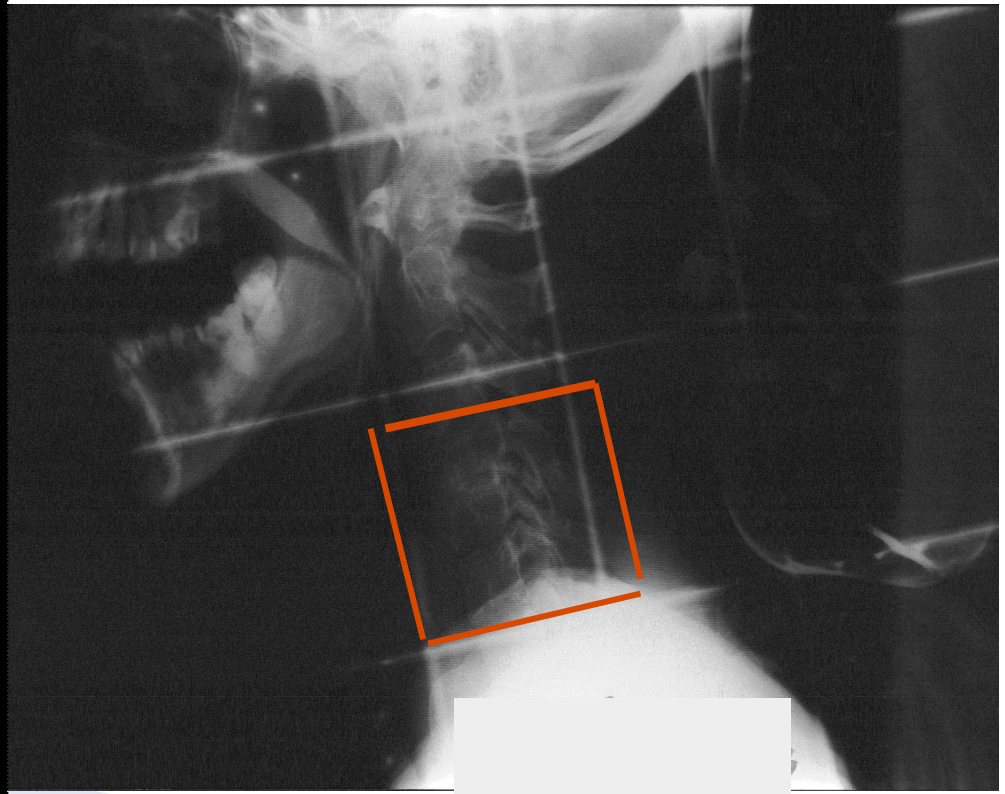
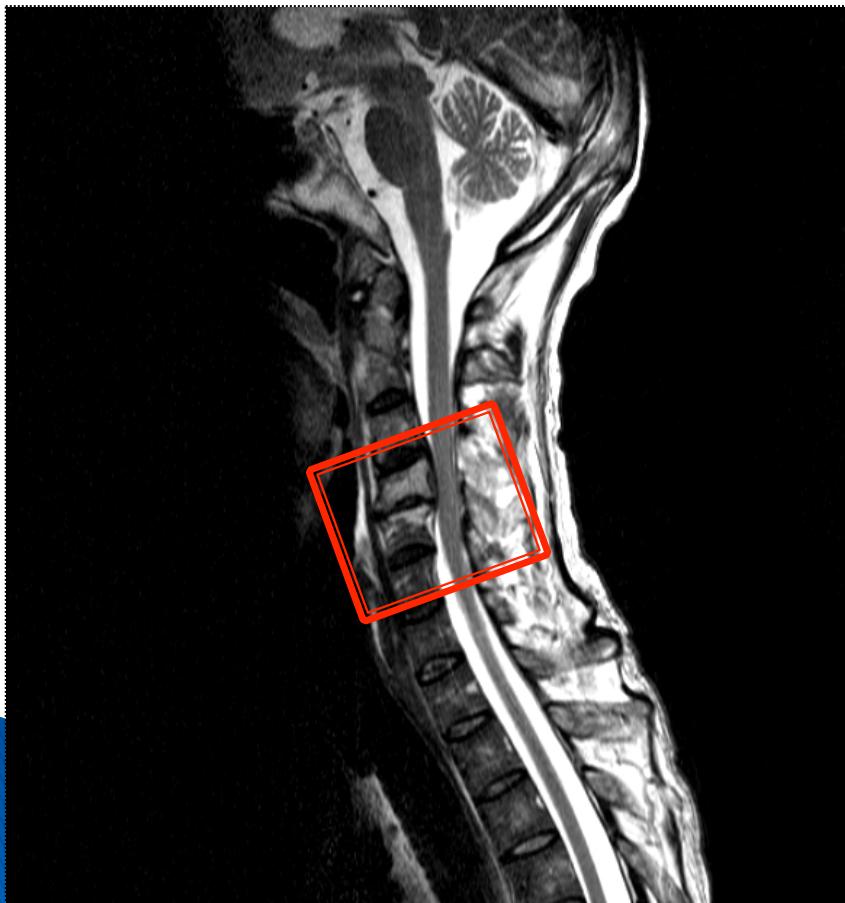
Es: metastasi vertebrale

Perché fare SBRT ?

- Dose ablativa e non palliazione (malattia non diffusa)
- Metastasi da primitivo radioresistente
- Malattia confinata ad una parte della vertebra
- Pregressa chemioterapia (mielotossicità)
- Reirradiazione



Volumi Tecnica d'irradiazione



Clinical Investigation: Central Nervous System Tumor

International Spine Radiosurgery Consortium Consensus Guidelines for Target Volume Definition in Spinal Stereotactic Radiosurgery

Brett W. Cox, MD,^{*,1} Daniel E. Spratt, MD,^{*,1} Michael Lovelock, PhD,[†]
Mark H. Bilsky, MD,[‡] Eric Lis, MD,[§] Samuel Ryu, MD,^{||} Jason Sheehan, MD,[¶]
Peter C. Gerszten, MD, MPH,^{**} Eric Chang, MD,^{††} Iris Gibbs, MD,^{‡‡} Scott Soltys, MD,^{‡‡}
Arjun Sahgal, MD,^{§§} Joe Deasy, PhD,[†] John Flickinger, MD,^{|||} Mubina Quader, PhD,^{|||}
Stefan Mindea, MD,^{¶¶} and Yoshiya Yamada, MD,^{¶¶}

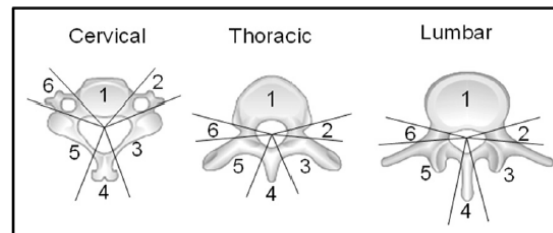


Fig. 1. International Spine Radiosurgery Consortium anatomic classification system for consensus target volumes for spine radiosurgery.

e604 Cox et al.

International Journal of Radiation Oncology • Biology • Physics

Table 4 Summary of contouring guidelines for GTV, CTV, and PTV in spinal stereotactic radiosurgery

Target volume	Guidelines
GTV	<ul style="list-style-type: none"> • Contour gross tumor using all available imaging • Include epidural and paraspinal components of tumor
CTV	<ul style="list-style-type: none"> • Include abnormal marrow signal suspicious for microscopic invasion • Include bony CTV expansion to account for subclinical spread • Should contain GTV • Circumferential CTVs encircling the cord should be avoided except in rare instances where the vertebral body, bilateral pedicles/lamina, and spinous process are all involved or when there is extensive metastatic disease along the circumference of the epidural space without spinal cord compression
PTV	<ul style="list-style-type: none"> • Uniform expansion around CTV • CTV to PTV margin ≤ 3 mm • Modified at dural margin and adjacent critical structures to allow spacing at discretion of the treating physician unless GTV compromised • Never overlaps with cord • Should contain entire GTV and CTV

Abbreviations: CTV = clinical target volume; GTV = gross tumor volume; PTV = planning target volume.

SRBT : Fattori che influenzano il controllo locale ,PFS ed OS

Fumagalli et al. *Radiation Oncology* 2012, 7:164
<http://www.ro-journal.com/content/7/1/164>

2012



7) Timing ?

RESEARCH

Open Access

A single-institution study of stereotactic body radiotherapy for patients with unresectable visceral pulmonary or hepatic oligometastases

Ingrid Fumagalli¹, Jean-Emmanuel Bibault¹, Sylvain Dewas¹, Andrew Kramar², Xavier Mirabel¹, Bernard Prevost¹, Thomas Lacomberie¹, Haier Jerrava³ and Eric Lartigau^{1*}

SBRT and previous chemotherapy regimens

We wondered whether or not pre-treated patients with metastatic disease could benefit from SBRT. Most of our patients had received prior chemotherapy (91%), with a high number of chemotherapy regimens, 27% of them receiving more than three regimens, which may have increased the radioresistance of the metastases. We found that a patient's history of prior chemotherapy was a major risk factor in recurrence outside the treatment volume (HR = 4.51, 95% CI: 1.10–18.47, p = 0.007). Also, the number of previous chemotherapy regimens

SRBT : Fattori che influenzano il controllo locale ,PFS ed OS

7) SBRT e CHT: timing ?

Fumagalli et al. *Radiation Oncology* 2012, 7:164
<http://www.ro-journal.com/content/7/1/164>



RESEARCH

Open Access

A single-institution study of stereotactic body radiotherapy for patients with unresectable visceral pulmonary or hepatic oligometastases

Ingrid Fumagalli¹, Jean-Emmanuel Bibault¹, Sylvain Dewas¹, Andrew Kamar², Xavier Mirabel¹, Bernard Prevost¹, Thomas Lacornerie¹, Hajer Jerraya³ and Eric Lartigau^{1*}

administered or progression while receiving chemotherapy significantly correlates with a higher risk of failure. One hypothesis that could explain this finding could be that the previous chemotherapy regimens, received by the patients, selected tumoral clones with a lower sensitivity to radiation, even if no study has been published to prove it. This suggests that SBRT should perhaps be used as a local treatment for metastases before the administration of several systemic therapies.


SRBT : Fattori che influenzano il controllo locale ,PFS ed OS

7) SBRT e CHT: timing ?

The possible existence of different cell population (chemosensitive & chemoresistant/radiosensitive & radioresistant) suggests the use of both therapeutic options

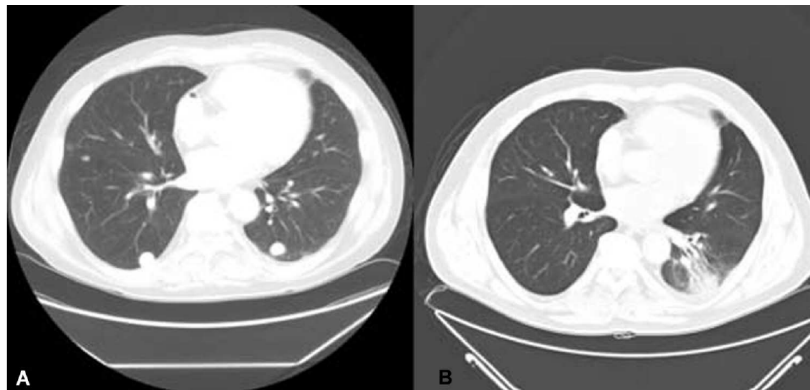
However,

**the association of chemo and SBRT can improve toxicity,
as well as biological therapy and SBRT!**



Phase 1 Study of Stereotactic Body Radiotherapy and Interleukin-2: Tumor and Immunological Responses

Steven K. Seung,^{1,2*} Brendan D. Curti,^{1,3*†} Marka Crittenden,^{1,2} Edwin Walker,¹



12 casi di melanoma e ca renale
SBRT 20 Gy x 3 3/7 gg prima della IL2

SBRT max 3 localizzazioni

8 paz (66.6%) RC o PR

1 paz stabile

3 pazienti in progressione

> CD4 – CD8 after

•Gli autori combinano IL-2 ad alte dosi RT stereotassica in base ad osservazioni cliniche di aumentata efficacia nei pazienti anche se deve ancora essere provata l' ipotesi secondo cui il **danno radio indotto induce il rilascio di antigeni tumorali e modifiche del microambiente capaci di aumentare l' effettoimmuno-attivante dell' IL-2.**

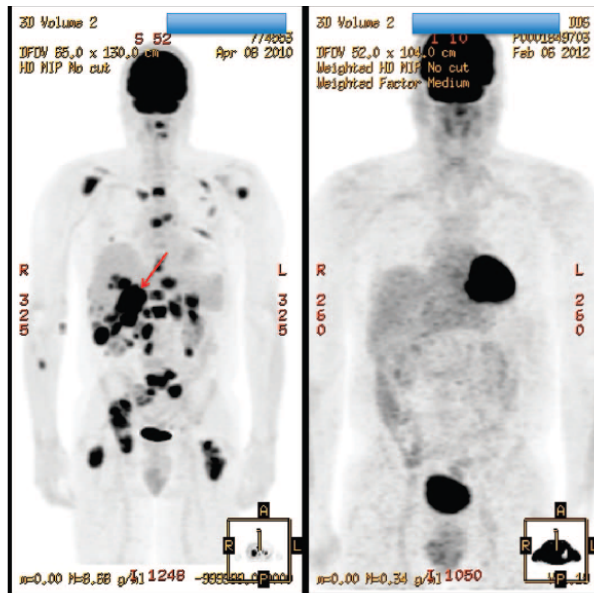
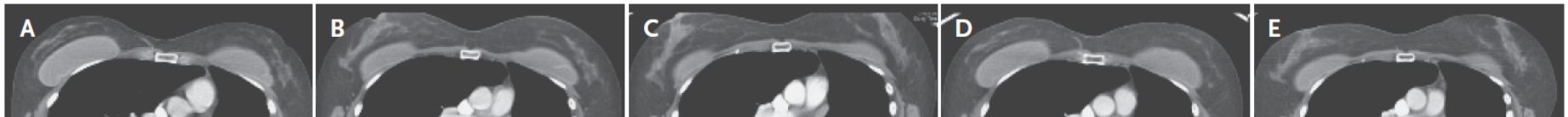

Fig. 2. Before and after PET imaging in a patient with widely metastatic melanoma. Two liver lesions were treated with SBRT.

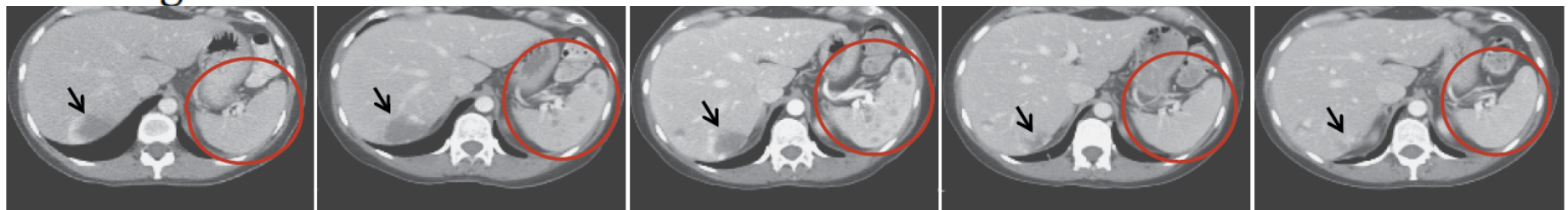2012

BRIEF REPORT

Immunologic Correlates of the Abscopal Effect in a Patient with Melanoma



THE ABS COPAL EFFECT REFERS TO A RARE PHENOMENON OF TUMOR REGRESSION at a site distant from the primary site of radiotherapy.¹ Localized radiotherapy has been shown to induce abscopal effects in several types of cancer, including melanoma, lymphoma, and renal-cell carcinoma.²⁻⁴ The biologic characteristics underlying this effect are not completely understood, but it may be mediated by immunologic mechanisms.⁵



August 2009

November 2010

January 2011

April 2011

October 2011

SRBT and abscopal effect

- 1) esaltazione della risposta immunitaria dell'ospite “innate ed adaptive”
- 2) incrementa la produzione di un interferon gamma peptide reattivo tumorale che produce cellule immunitarie antitumorali e la loro diffusione verso il drenaggio linfatico del tumore

Lugade AA et al: Local radiation therapy of B16 melanoma tumors increases the generation of tumor antigen-specific effector cells that traffic to the tumor. J Immunol 2005

- 3) Attivazione di TLR 4 attraverso proteine tumorali

Apetoh L et al: Toll-like receptor 4-dependent contribution of the immune system to anticancer chemotherapy and radiotherapy. Nat Med 2007

- 4) Attivazione e immissione di CD8 T cell nel drenaggio linfatico (dopo 20 Gy con stereobody)

Lee Y et al: Therapeutic effects of ablative radiation on local tumor require CD8 T cells: Changing strategies for cancer treatment. Blood 2009



Concurrent Ipilimumab and Stereotactic Ablative Radiation Therapy (SART) for Oligometastatic But Unresectable Melanoma. <http://clinicaltrials.gov/>

SBRT Metastasi polmonari e tox

Table 1. Outcomes of stereotactic body radiation therapy for lung metastases from selected trials

Study	n of patients	Median dose/n of fractions	Median (range) follow-up, mos	Local control rate	Overall survival	Toxicity
Onimaru et al. [5]	45	48 Gy/8; 60 Gy/8	18 (2–44)	3-yr, 69.6% for 48 Gy, 100% for 60 Gy	2-yr, 47.1%	Grade 5, 1 (2.2%)
Wulf et al. [32]	27	30 Gy/3; 36 Gy/3	13–17	2-yr, 71%	1-yr, 48% 2-yr, 21%	Grade 3, 1 (3.7%) Grade 5, 1 (3.7%)
Yoon et al. [71]	53	30 Gy/3; 40 Gy/4; 48 Gy/4	14 (4–56)	70% for 30 Gy, 77% for 40 Gy, 100% for 48 Gy	1-yr, 89%; 2-yr, 51%	Grade ≥2, 0%
Okunieff et al. [18]	50	50 Gy/10; 48 Gy/6; 57 Gy/3	18.7 (3.7–60.9)	3-yr, 91%	2-yr, 50%	Grade 2, 6.1% Grade 3, 2%
Norihisa et al. [6]	34	48 Gy/4; 60 Gy/5	27 (10–80)	2-yr, 90%	2-yr, 84%	Grade 2, 4 (12%) Grade 3, 1 (3%)
Brown et al. [72]	35	5 Gy/1 to 60 Gy/4	18 (2–41)	Crude, 77%	2-yr, 72.5%	Grade 3–4, 1 (2.8%)
Rusthoven et al. [14]	38	60 Gy/3	15.4 (6–48)	2-yr, 96%	2-yr, 39%	No grade 4 Grade 3, 3 (8%)
Ricardi et al. [17]	61	45 Gy/3; 26 Gy/1	20.4 (3–77)	2-yr, 89%	2-yr, 66.5	Grade 3, 1 (1.6%)

Original article

Central thoracic lesions treated with hypofractionated stereotactic body radiotherapy

Michael T. Milano *, Yuhchyan Chen, Alan W. Katz, Abraham Philip, Michael C. Schell, Paul Okunieff

Department of Radiation Oncology, University of Rochester Medical Center, NY, USA

Institution	Patient population	Prescribed dose (Gy)	Fraction dose (Gy)	BED2 (Gy)	Toxicity
IndianaU.	Stage I NSCLC	60-66	20-22	219-258	11-Fold increase risk of severe-fatal toxicity
Hokkaido U	NSCLC and Mts	48	6	64	1 of 9 with severe toxicity
U. Texas, San Antonio	NSCLC and Mts	36	6-12	86-126	1 of 9 – asymptomatic airway collapse
Air Force General Hospital	Stage I-II NSCLC	60-70 40-50	6-7 4-5	120-167	No severe toxicity
VU Amsterdam	Stage I NSCLC	60	7.5	88	No severe toxicity
Technical U.	NSCLC and Mts	35	7	105	No severe toxicity

Moderately hypofractionated SBRT to central thoracic lesions is effective with respect to local control and toxicity.

TOSSICITA' *Polmonite attinica*

Early phase – radiation pneumonitis (dispnea, tosse, febbre, fastidi)

non apprezzabile fino a 30 Gy

1-6 mesi dal termine della RT

Furuse 1999 Choi 2004


Later phase – radiation fibrosis (tosse, cuore polmonare)

Deposizione di collagene

Da 6 A 12 mesi dal termine della RT

Koenig 2002

Linda 2009



Tre fasi sequenziali:

1) *Fase acuta essudativa*

2) *Fase proliferativa e di organizzazione*

Infiltrazione più o meno organizzata di macrofagi

3) *Fase cronica con fibrosi*

Deposizione progressiva di collagene

polmonite

Park 2000

Simile alla BOOP



Tossicità polmonare dopo RT

Variabili

Legate al trattamento

Dose (il tempo di insorgenza di una tox 3D è simile alla RT convenzionale; per la SBRT cresce invece la probabilità di un danno tardivo)

Frazione volume

Tipologia del trattamento

V20 (4% per SBRT - 30/35% per 3D)

Legate al paziente

PS

Patologie polmonari

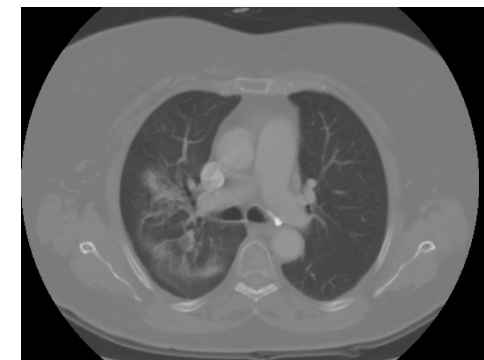
Pregressa Chemioterapia

Pregressa RT

Sede (centrale o periferica)

TOSSICITA' **Modificazioni radiologiche precoci (entro 6 mesi)** (Classificazione Ikezoe)

- | | |
|--------------------------------------------------------------------------------|--------|
| ▶ Diffuse consolidation
(consolidation more than 5 cm in largest dimension) | 20-30% |
| ▶ Patchy consolidation
(consolidation less than 5 cm in largest dimension) | 8-22% |
| ▶ Diffuse ground glass opacities
(more than 5 cm of GGO) | 4-8% |
| ▶ Patchy ground glass opacities
(less than 5 cm of GGO) | 10-15% |



Diffuse ground glass opacities


Tossicità polmonari precoci dopo RT

Le alterazioni visibili alla TC dopo SBRT o 3D sono differenti rispetto alla radioterapia convenzionale . Differiscono in:

- 1) Caratteristiche morfologiche
- 2) Estensione
- 3) Distribuzione

3D focale o nodulare opacità vetro smerigliato aree di consolidazione o entrambe con *reperti situati immediatamente intorno al tumore trattato*
In altri casi i reperti radiologici *possono essere localizzati al di fuori del target*, anche se confinati all' interno del campo di irradiazione

SBRT Le alterazioni radiologiche sono visibili *solo all' interno del target* a causa dell' alto gradiente di dose



TOSSICITA' Polmonite

Polmonite da radiazioni (13-37%) dopo RT 3D
(V20 o con la MLD (V20 > 30-35%).


Armstrong 2000 Rodrigues 2004

Se la V20 è <25% minime alterazioni

Graham 1999

Polmonite da radiazioni dopo SBRT (4%) $v_{20} = 3-10\%$

Aoki 2004 Trovò 2010



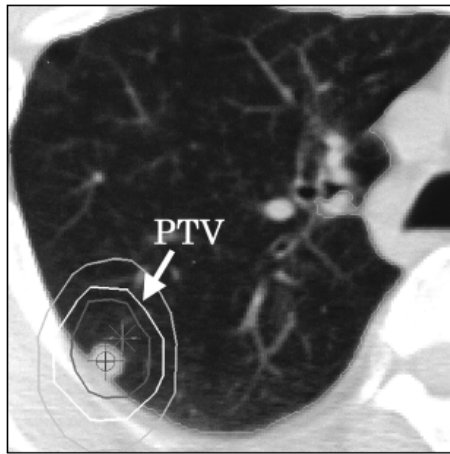
Radiation Injury After Hypofractionated Stereotactic Radiotherapy for Peripheral Small Lung Tumors: Serial Changes on CT

Toshiaki Takeda¹ AJR 2006

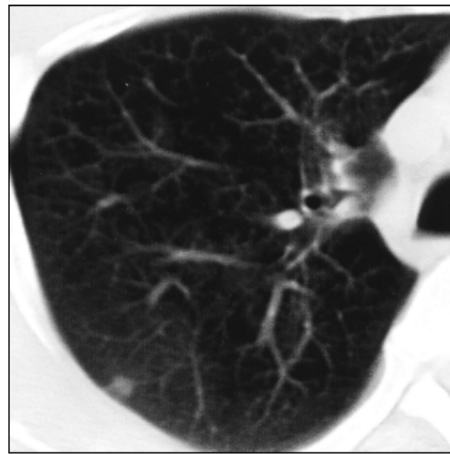
OBJECTIVE. We studied the serial changes and CT manifestations of pulmonary radia

1 mese

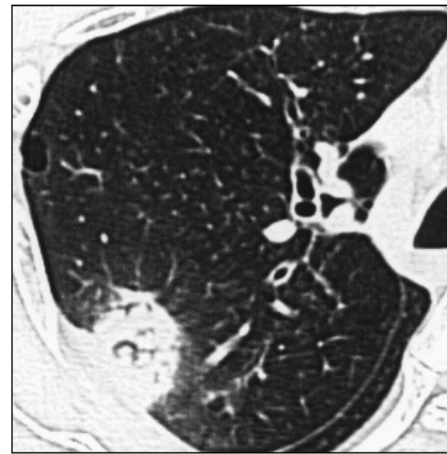
4 mesi



A



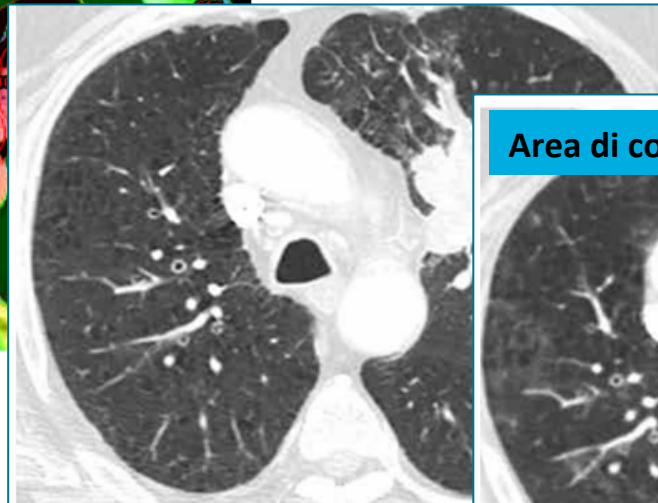
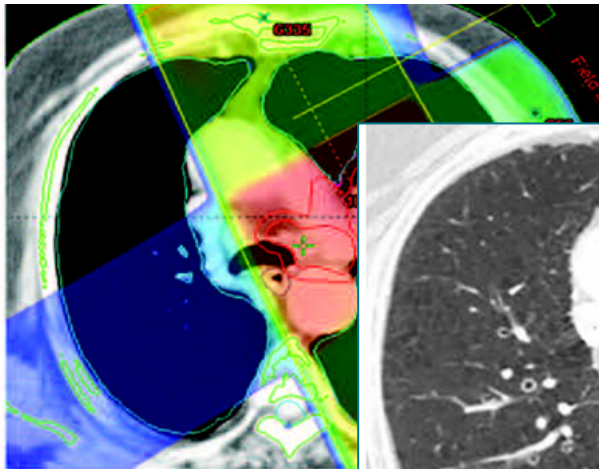
B



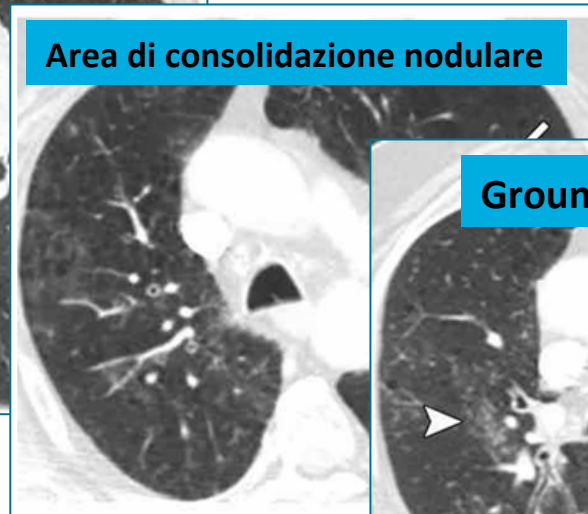
C

Patchy ground-glass opacity.


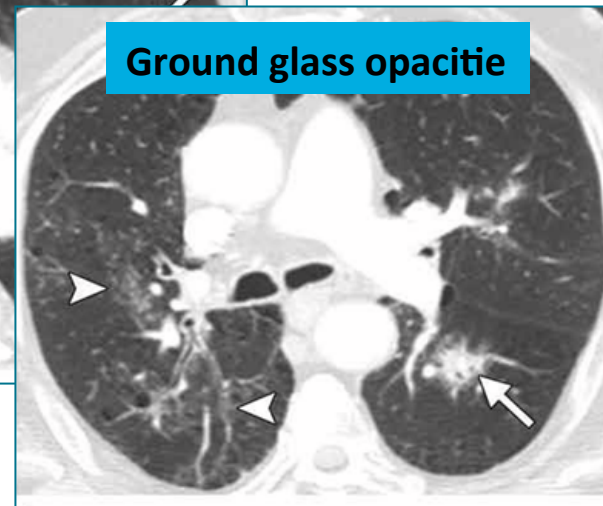
Lung Abnormalities at Multimodality Imaging after Radiation Therapy for Non-Small Cell Lung Cancer ¹



Area di consolidazione nodulare

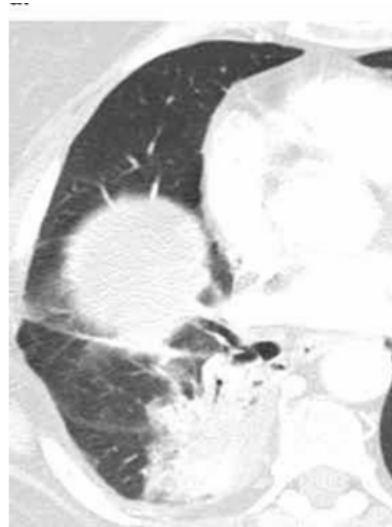
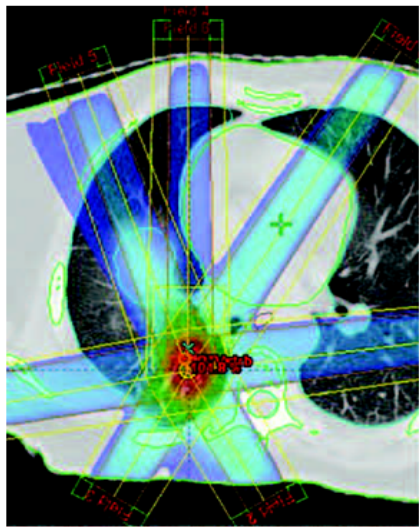


Ground glass opacities




2011

Lung Abnormalities at Multimodality Imaging after Radiation Therapy for Non-Small Cell Lung Cancer 1



2 mesi

Diffusa consolidazione



TOSSICITA' Modificazioni radiologiche tardive (oltre 6 mesi)

2011

EDUCATION EXHIBIT

9

RadioGraphics

Effects of Radiation Therapy on the Lung: Radiologic Appearances and Differential Diagnosis¹

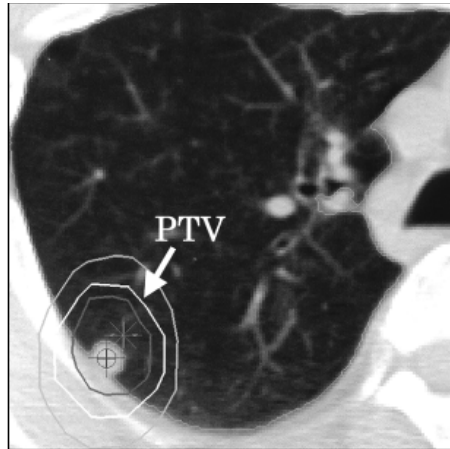
Yo Won Choi, MD • Reginald F. Munden, MD • Jeremy J. Erasmus, MD

- Area ben definita di regressione tumorale
- Cicatrici lineari (linear scarring)
- Aree di consolidamento
- Bronchiectasie da trazione
- retrazione da trazione con movimenti verso l'ilo

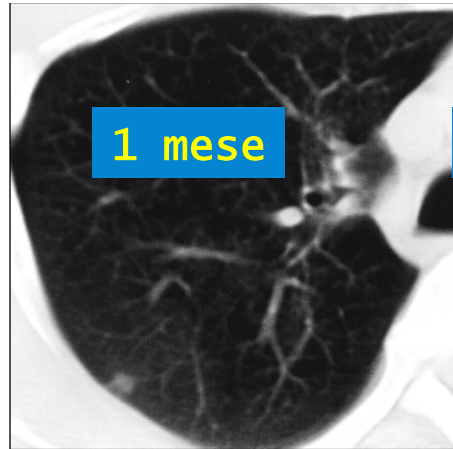
Radiation Injury After Hypofractionated Stereotactic Radiotherapy for Peripheral Small Lung Tumors: Serial Changes on CT

Toshiaki Takeda¹ AJR 2006

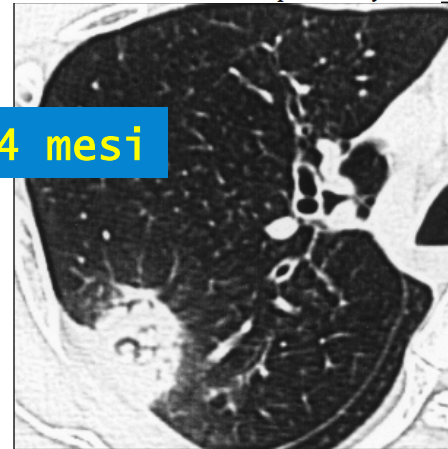OBJECTIVE. We studied the serial changes and CT manifestations of pulmonary radia



A

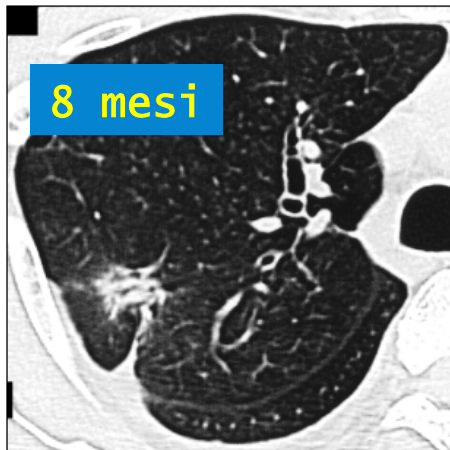


B

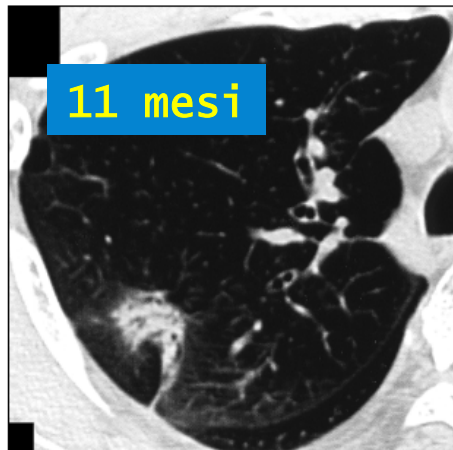


C

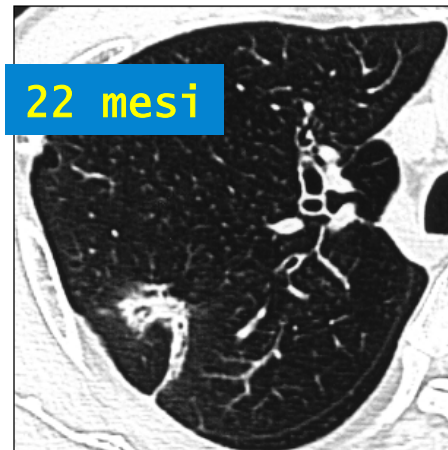
Patchy ground-glass opacity.



D



E

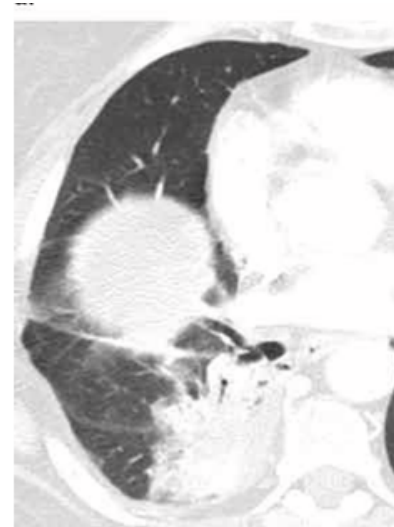



F

shrinkage of dense consolidation, dilated bronchi, fixation of opacity

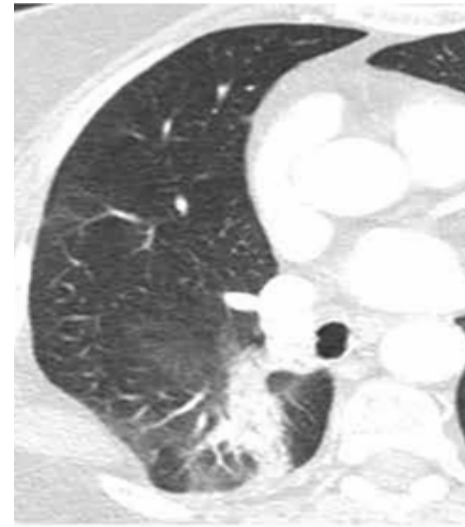2011

Lung Abnormalities at Multimodality Imaging after Radiation Therapy for Non-Small Cell Lung Cancer 1




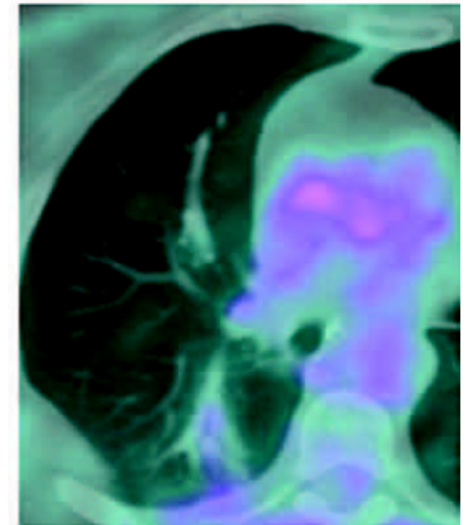
2 mesi

Diffusa consolidazione



9 mesi

Retrazione della
consolidazione



TOSSICITA ' Modificazioni radiologiche tardive

2002


Radiation Injury of the Lung After Three-Dimensional Conformal Radiation Therapy

Titus R. Koenig¹

OBJECTIVE. The objective of this study is to describe the CT patterns of radiation injury in the

Fibrosi radioindotta

- Modified conventional pattern
- Mass-like pattern
- Scar-like pattern



TOSSICITA ' Modificazioni radiologiche tardive

2002

Radiation Injury of the Lung After Three-Dimensional Conformal Radiation Therapy

Titus R. Koenig¹

OBJECTIVE. The objective of this study is to describe the CT patterns of radiation injury in the

Fibrosi radioindotta

- **Modified conventional pattern**
 - Mass-like pattern
 - Scar-like pattern
- **Opacità a margini netti**
- **Perdita di volume**
- **Bronchiectasie da trazione**
- **Minore estensione rispetto alla RT convenzionale**
- **Può modificarsi la localizzazione nel primo anno di comparsa con dislocazione verso l' ilo o lontano dall' ilo**

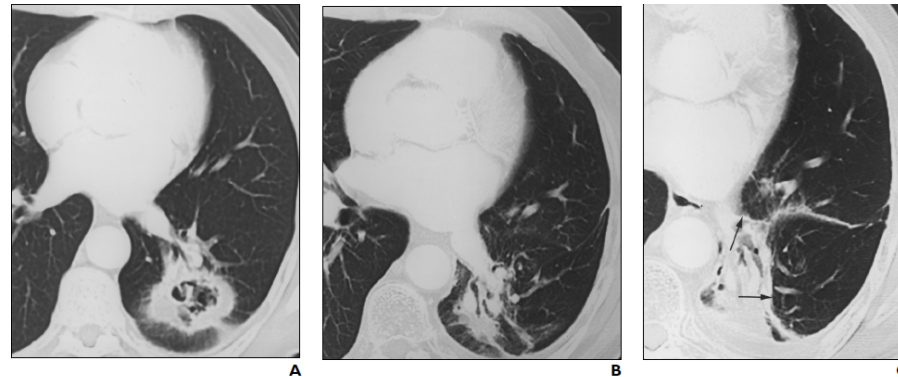


Fig. 3.—Modified conventional pattern in 81-year-old man with squamous cell carcinoma.
A. Pretreatment CT scan shows cavitary mass in left lower lobe.
B. CT scan obtained 10 months after completion of radiation therapy shows decrease in size of mass and development of consolidation indicating organizing fibrosis.
C. CT scan obtained 22 months after completion of radiation therapy shows well-defined area (arrows) of consolidation, volume loss, and traction bronchiectasis typical of radiation fibrosis. Note lung anterior to fibrosis is normal.

TOSSICITA ' Modificazioni radiologiche tardive

2002

Radiation Injury of the Lung After Three-Dimensional Conformal Radiation Therapy

Titus R. Koenig¹

OBJECTIVE. The objective of this study is to describe the CT patterns of radiation injury in the

Fibrosi radioindotta

- Modified conventional pattern
- Mass-like pattern
- Scar-like pattern

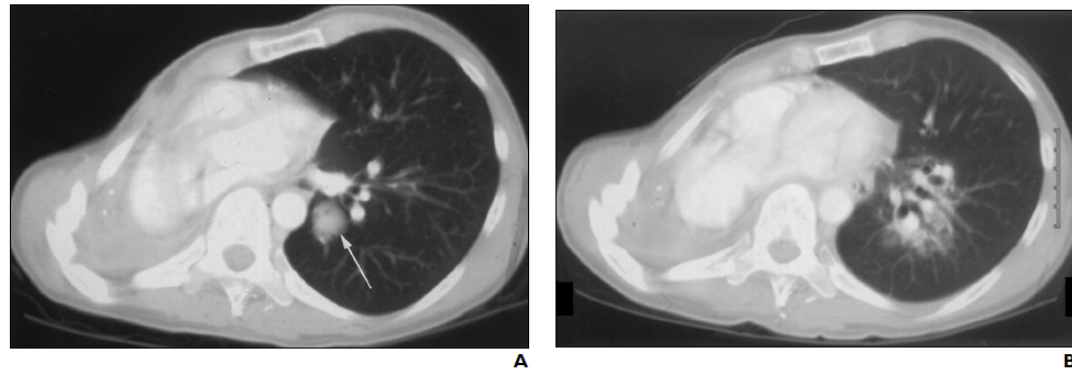


Fig. 4.—Masslike pattern in 44-year-old woman with adenoid cystic carcinoma. Note right pneumonectomy.
A. Pretreatment CT scan shows well-circumscribed mass (*arrow*) in left lower lobe.
B. CT scan obtained 21 months after completion of radiation therapy shows consolidation and bronchiectasis at tumor site that resembles mass.

- Aree di consolidazione focale situata 2 cm oltre il tumore
- Corrisponde alla zona con più alta dose
- Può modificarsi la localizzazione nel primo anno di comparsa con dislocazione verso l'ilo o lontano dall'ilo

TOSSICITA' Modificazioni radiologiche tardive

2002

Radiation Injury of the Lung After Three-Dimensional Conformal Radiation Therapy

Titus R. Koenig¹

OBJECTIVE. The objective of this study is to describe the CT patterns of radiation injury in the

Fibrosi radioindotta

- Modified conventional pattern
- Mass-like pattern
- Scar-like pattern (cicatrice)

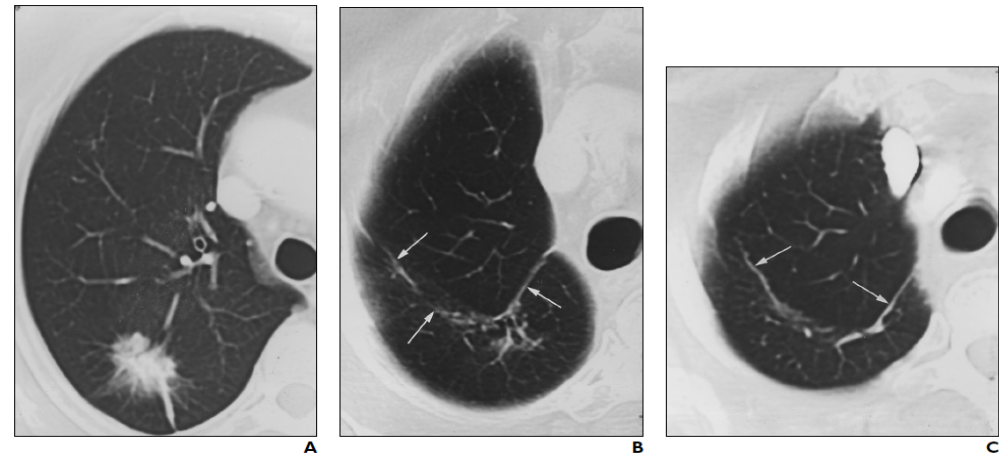


Fig. 5.—Scarlike pattern in 60-year-old woman with adenocarcinoma.
A, Pretreatment CT scan shows spiculated lesion in right upper lobe.
B, CT scan obtained 11 months after radiation therapy shows linear area of consolidation (arrows) with volume loss and no evidence of residual tumor.
C, CT scan obtained 36 months after completion of radiation therapy shows only linear band (arrows) that resembles scar.

- Opacità lineari ampie < 1 cm
- Perdita di volume moderata o cospicua e che rimane presente alla TC nel sito del tumore quando questo è completamente o quasi completamente scomparso

TOSSICITA ' Modificazioni radiologiche tardive

2002


Radiation Injury of the Lung After Three-Dimensional Conformal Radiation Therapy

Titus R. Koenig¹

OBJECTIVE. The objective of this study is to describe the CT patterns of radiation injury in the

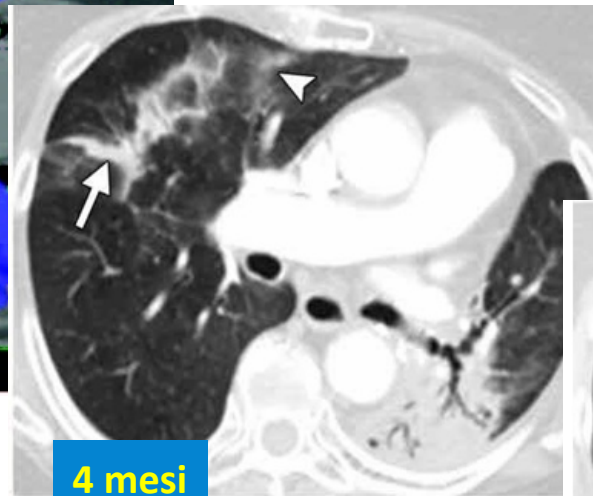
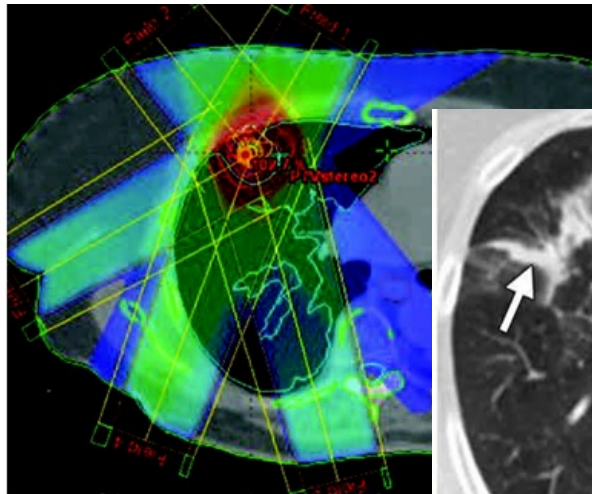
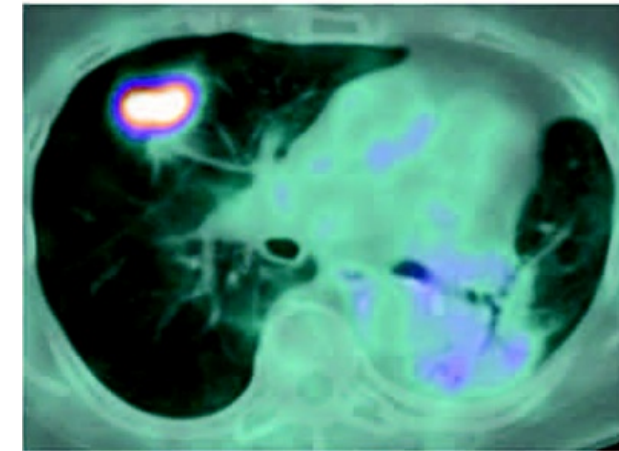
Fibrosi radioindotta

- Modified conventional pattern
 - Mass-like pattern
 - Scar-like pattern
- **Diagnosi differenziali:**
- Infezioni
 - Linfangiti carcinomatose
 - Neoplasie radioindotte
 - **Recidive locali o persistenze di malattia**

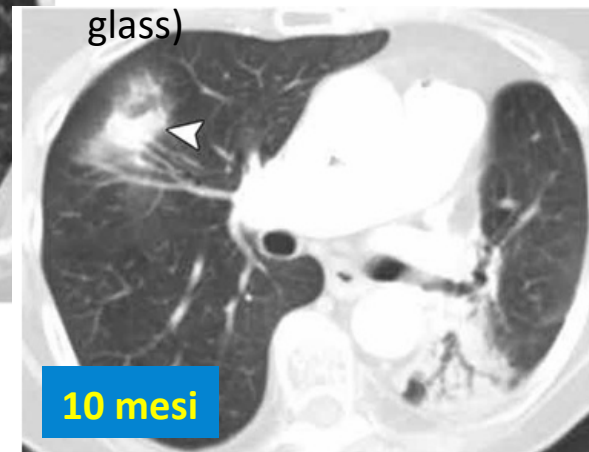

CHEST IMAGING

Lung Abnormalities at Multimodality Imaging after Radiation Therapy for Non-Small Cell Lung Cancer 1



consolidazione a chiazze (patchy)
e opacità a vetro smerigliato (ground
glass)



Non bronchiectasie da trazione

CONCLUSIONI

- Da risultati preliminari pubblicati, grazie alla più estensiva prescrizione SBRT, il ruolo della RT nella malattia metastatica si è evoluto dalla palliazione dei sintomi ad un obiettivo potenzialmente curativo
- Nel sottogruppo di pazienti con metastasi solitaria studi investigazionali di dose escalation con SBRT possono essere utili per ottimizzare il controllo locale
- Nei casi con più di una metastasi specialmente se più di un organo è coinvolto I criteri di selezione per SBRT devono essere valutati con attenzione verso l'aspettativa di vita e la tossicità

Thariat et al. Bull Cancer, 2010

Timmerman et al JCO, 2007

Lartigau Et al, Radiat oncol 2012



SBRT : argomenti aperti

- Quale è il reale cut off tra la palliazione pura e l'ipotetico intento curativo nei pazienti oligometastatici
- Quale è il target ottimale e come può il radioterapista definirlo nel migliore dei modi possibili (malattia microscopica)
- Quale è il corretto timing con la cht?.
- Combinazione con i nuovi farmaci e la stereobody
- Validazione del suo ruolo attraverso trials clinici dedicati (dose, outcome)



SBRT: Riflessioni

None of these treatment delivery units is superior to the others, with each system clearly having its strengths and weaknesses.

The training and experience of the SBRT team are much more important than the treatment delivery unit used.

Shagal Radiosurgery 2010





Grazie per l'attenzione