

Ud'A
Università degli Studi "G. d'Annunzio"

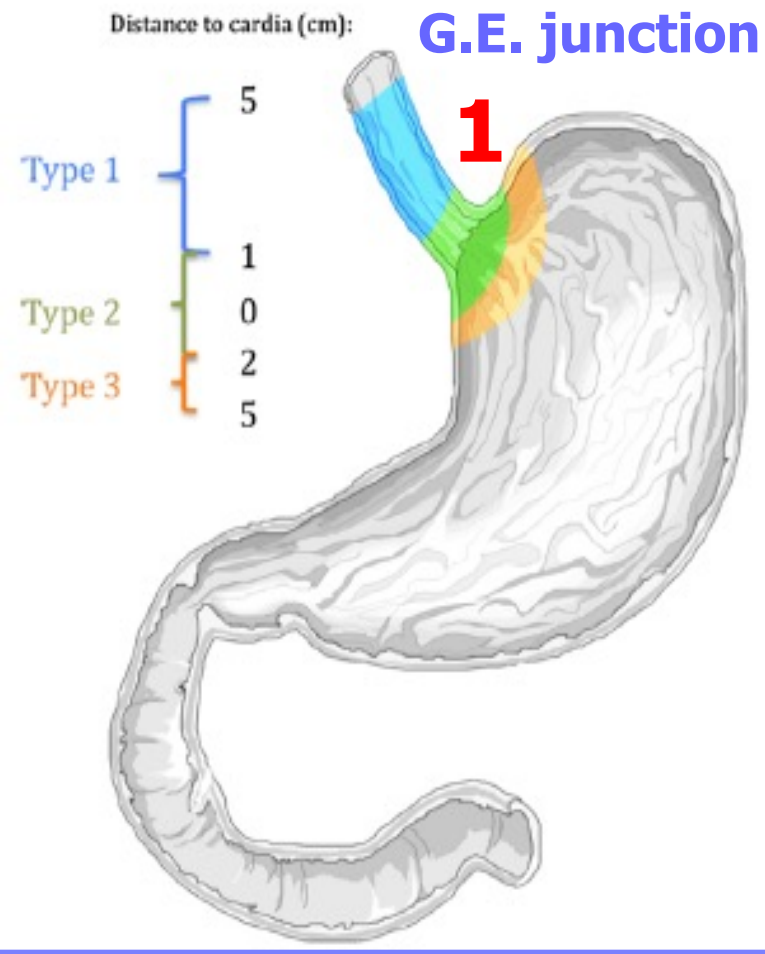
Target delineation in Gastric Cancer adjuvant Radiotherapy

D. Genovesi

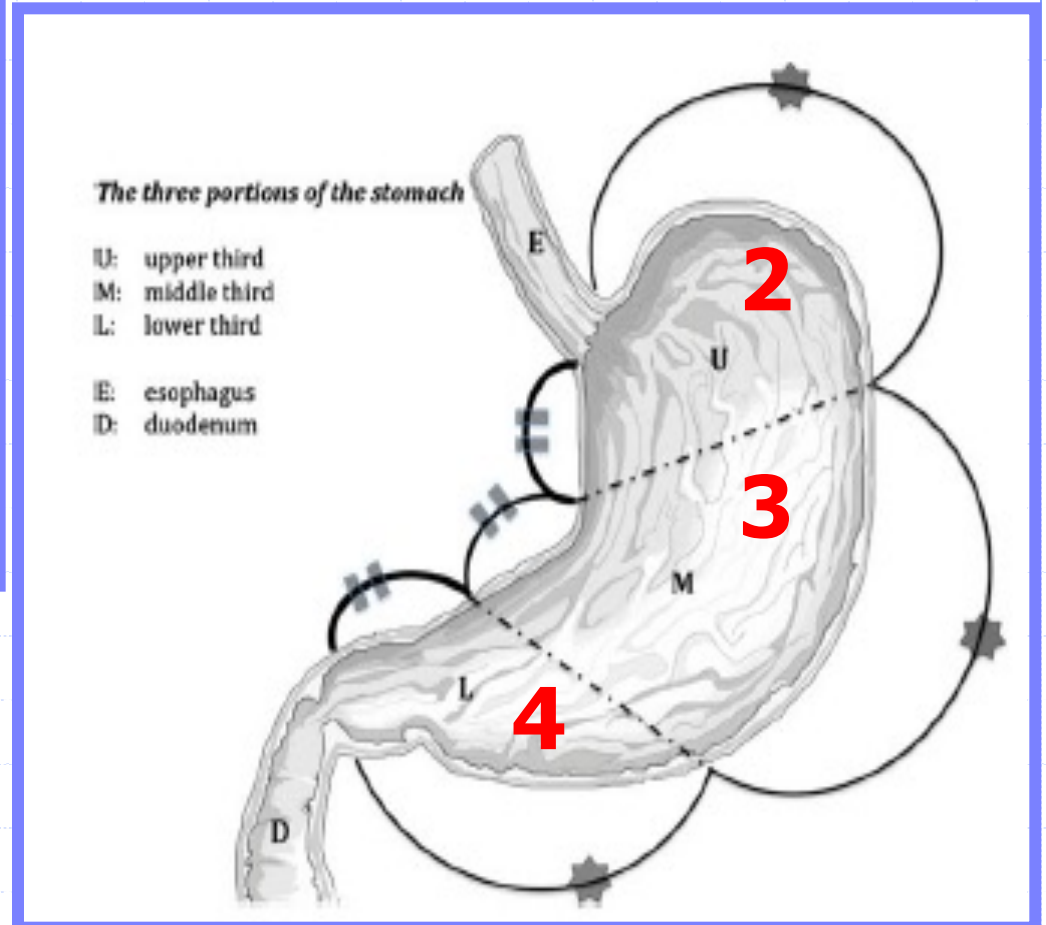
Istituto di Radioterapia Oncologica CHIETI

www.radioterapia.unich.it



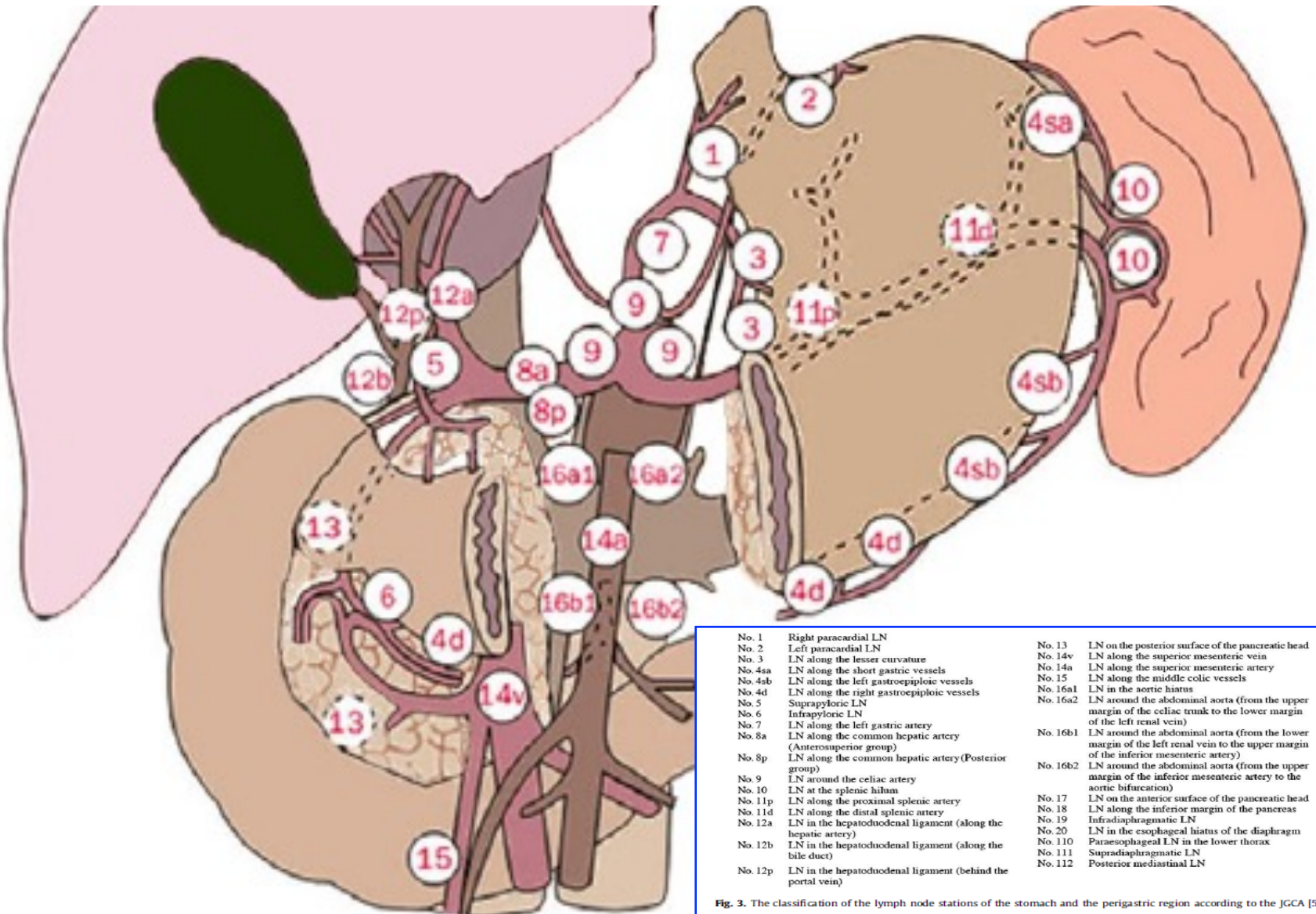


Sites of Primary Gastric Tumors



Classification of Lymph node stations

JGCA 1998



- | | | | |
|---------|--|----------|--|
| No. 1 | Right paracardial LN | No. 13 | LN on the posterior surface of the pancreatic head |
| No. 2 | Left paracardial LN | No. 14v | LN along the superior mesenteric vein |
| No. 3 | LN along the lesser curvature | No. 14a | LN along the superior mesenteric artery |
| No. 4sa | LN along the short gastric vessels | No. 15 | LN along the middle colic vessels |
| No. 4sb | LN along the left gastroepiploic vessels | No. 16a1 | LN in the aortic hiatus |
| No. 4d | LN along the right gastroepiploic vessels | No. 16a2 | LN around the abdominal aorta (from the upper margin of the celiac trunk to the lower margin of the left renal vein) |
| No. 5 | Suprapyloric LN | No. 16b1 | LN around the abdominal aorta (from the lower margin of the left renal vein to the upper margin of the inferior mesenteric artery) |
| No. 6 | Infrapyloric LN | No. 16b2 | LN around the abdominal aorta (from the upper margin of the inferior mesenteric artery to the aortic bifurcation) |
| No. 7 | LN along the left gastric artery | No. 17 | LN on the anterior surface of the pancreatic head |
| No. 8a | LN along the common hepatic artery (Anterosuperior group) | No. 18 | LN along the inferior margin of the pancreas |
| No. 8p | LN along the common hepatic artery (Posterior group) | No. 19 | Infradiaphragmatic LN |
| No. 9 | LN around the celiac artery | No. 20 | LN in the esophageal hiatus of the diaphragm |
| No. 10 | LN at the splenic hilum | No. 110 | Parasophageal LN in the lower thorax |
| No. 11p | LN along the proximal splenic artery | No. 111 | Supradiaphragmatic LN |
| No. 11d | LN along the distal splenic artery | No. 112 | Posterior mediastinal LN |
| No. 12a | LN in the hepatoduodenal ligament (along the hepatic artery) | | |
| No. 12b | LN in the hepatoduodenal ligament (along the bile duct) | | |
| No. 12p | LN in the hepatoduodenal ligament (behind the portal vein) | | |

Fig. 3. The classification of the lymph node stations of the stomach and the perigastric region according to the JGCA [58].

Localized Gastric or Gastroesophageal Cancer – Chemoradiation Is a Pertinent Component of Adjuvant Treatment for Patients at High Risk of Relapse

Leonard L. Gunderson, Matthew D. Callister, Dawn E. Jaroszewski, Helen J. Ross, Mitesh J. Borad, Richard J. Gray, Louis A. Lanza, Kristi L. Harold, Barbara A. Pockaj, Victor F. Trastek

Gastrointest Cancer Res 3(suppl 1):S26–S32. ©2009

Table 2. Local-regional relapse after node dissection of gastric cancer, University of Minnesota Reoperation Series.^{4,5}

Node Dissection*	No. pts at risk	Relapse in LN or LN Dissected Area	
		Only LF-RF No. (%)	Component† No. (%)
Method 1	25	2 (8)	11 (44)
Method 2	29	3 (10)	20 (69)
Method 3	26	3 (12)	13 (50)
Unknown	2	0	1
Totals	82	8 (10)	45 (55)

D2-D3

Abbreviations: LF-RF = local-regional failure/relapse; LN = lymph node.

*Method 1 – Subtotal or total gastrectomy, greater omentectomy, regional node dissection; Method 2 – Method 1 + splenectomy, total omentectomy, added node dissection—splenic, suprapancreatic, central celiac axis; Method 3 – Methods 1 and 2 plus extension of node dissection to porta hepatis and pancreatico-duodenal—equivalent to D2 or D3 node dissection.

† LR-RF as a component of failure.

Gastric Cancer

Lymph-node Metastasis by Tumour Site

	Incidence (%)		
	Upper 3rd	Middle 3rd	Lower 3rd
□ N ₁ □ N ₂			
Paracardial	22	9	4
less/greater c.	25	36	37
Supra/infra pyloric	5	18	61
Hepatic artery	7	11	25
Celiac axis	13	8	13
Splenic a./ilum	11	3	2
Hepatic pedicle	1	2	8

1931 patients

K.Maruyama et al., Ann Surg 1989

Clinical Target Volumes

- *postoperative setting*
- *CTVs/Tumor site*

Variability in CTV delineation



ELSEVIER

Int. J. Radiation Oncology Biol. Phys., Vol. 77, No. 4, pp. 1166–1170, 2010

Copyright © 2010 Elsevier Inc.

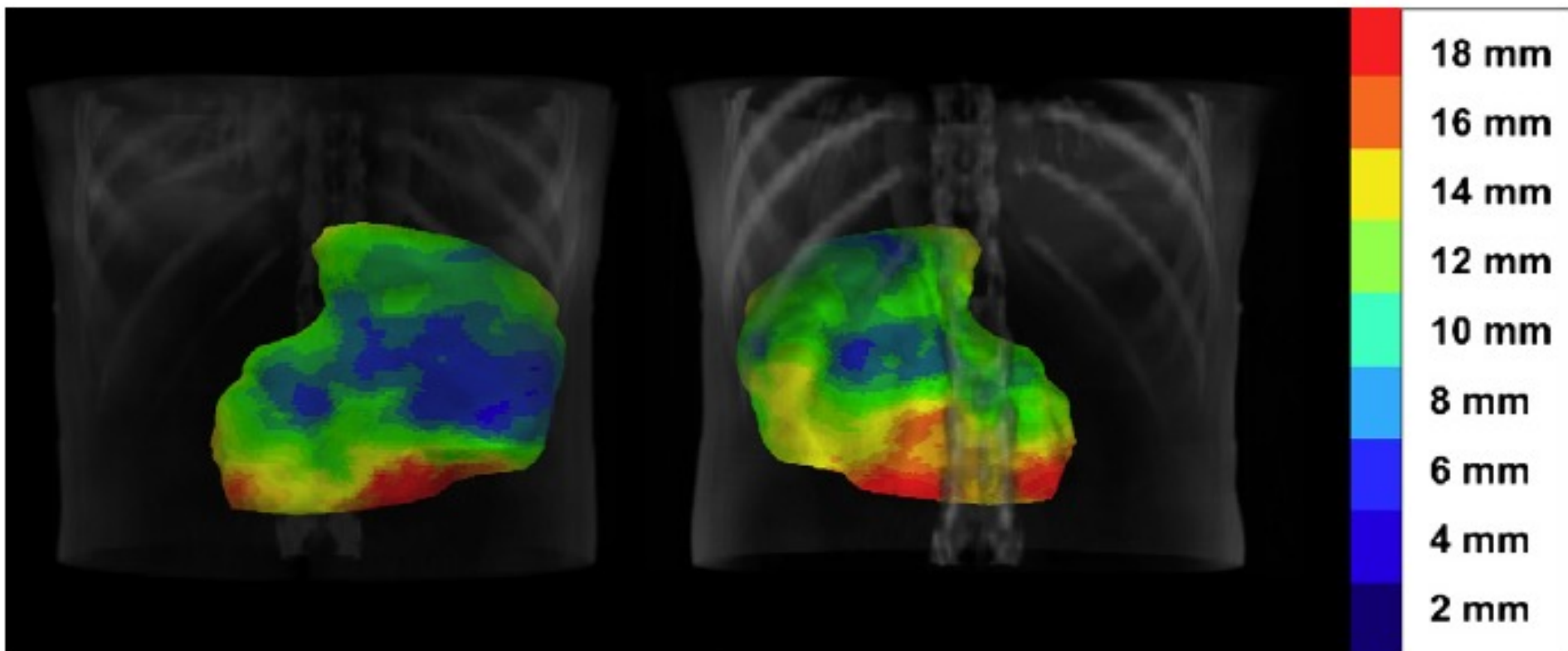
Printed in the USA. All rights reserved.

0360-3016/\$—see front matter

doi:10.1016/j.ijrobp.2009.06.023

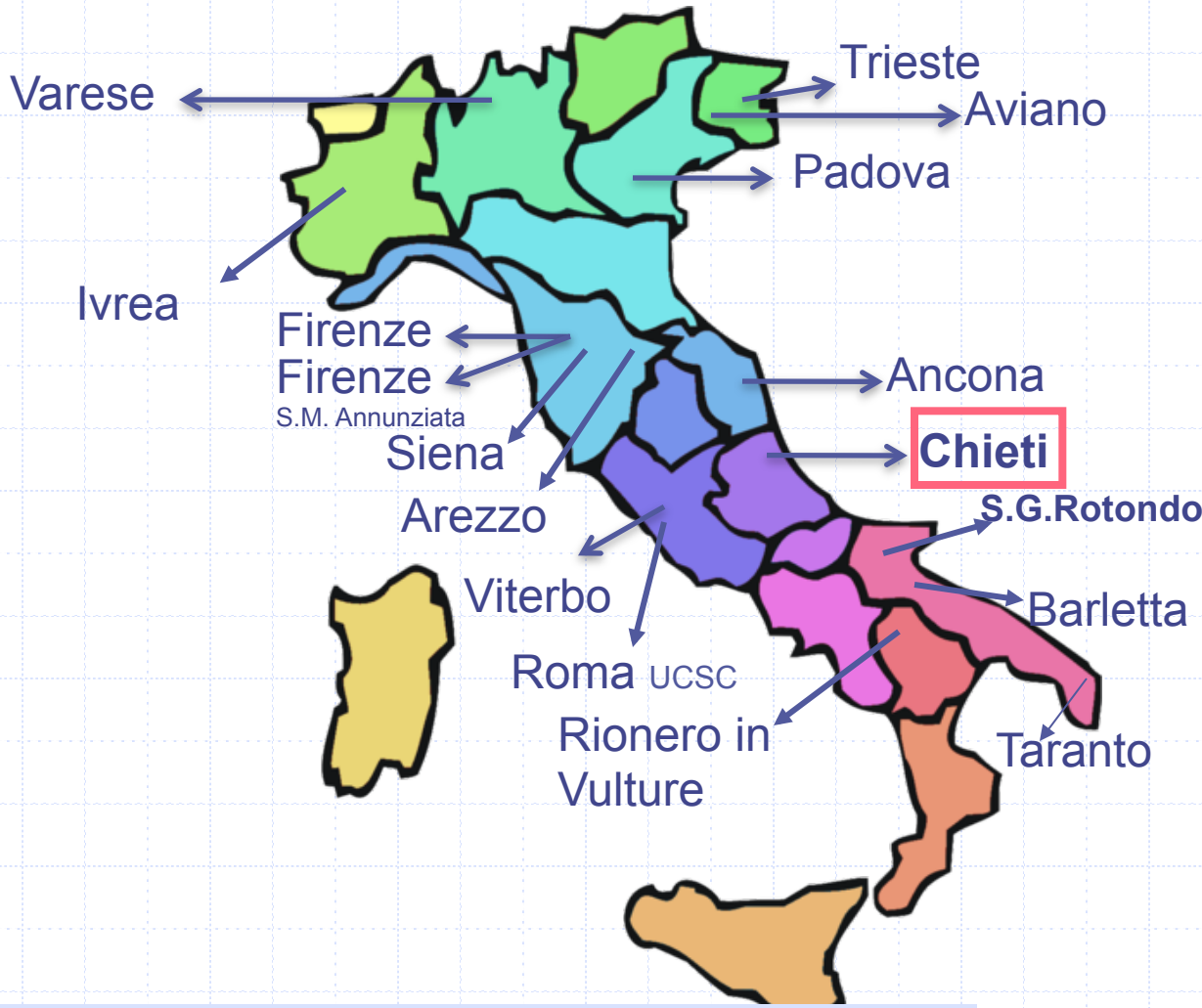CLINICAL INVESTIGATION

Stomach



is large. Strict and clear delineation guidelines should be provided, especially in Phase III multicenter studies. Adaptations of these guidelines should be evaluated in clinical studies. © 2010 Elsevier Inc.

PARTICIPANTS (Centers)



Gastro-Intestinal AIRO Working Group



LA RADIOTERAPIA NEL CARCINOMA GASTRICO

Indicazioni Cliniche e Criteri Guida di Trattamento



COORDINATORI DEL CORSO
A. DE PAOLI, A. GALARDI, V. FUSCO

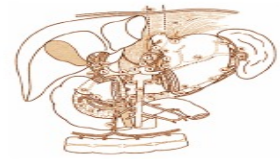CENTRO DI RIFERIMENTO ONCOLOGICO
ISTITUTO NAZIONALE TUMORI-AVIANO
CRO
AVIANO

AVIANO 24 GIUGNO 2011
FIRENZE 28 SETTEMBRE 2011
RIONERO IN VULTURE 20 OTTOBRE 2011



LA RADIOTERAPIA NEL CARCINOMA GASTRICO

Indicazioni Cliniche e Criteri Guida di Trattamento



COORDINATORI DEL CORSO
A. DE PAOLI, A. GALARDI, V. FUSCO

UNIVERSITA' DEGLI STUDI DI FIRENZE
DIPARTIMENTO DI RADIOTERAPIA DI AREA NASTA
UNIFE

AVIANO 24 GIUGNO 2011
FIRENZE 28 SETTEMBRE 2011
RIONERO IN VULTURE 20 OTTOBRE 2011



LA RADIOTERAPIA NEL CARCINOMA GASTRICO

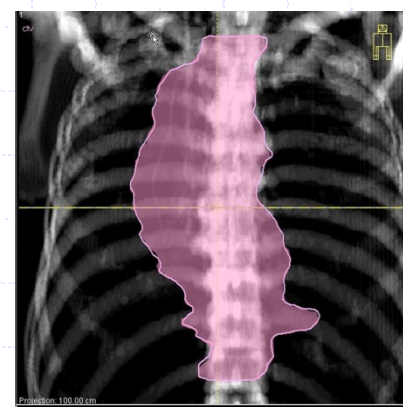
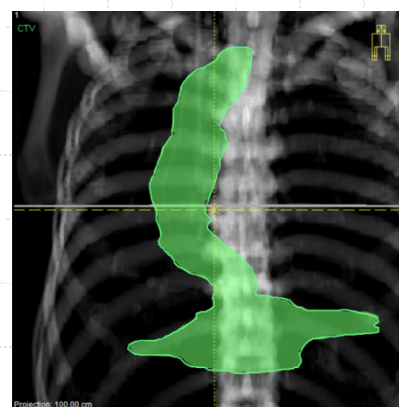
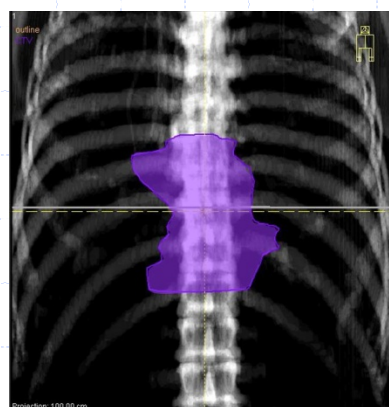
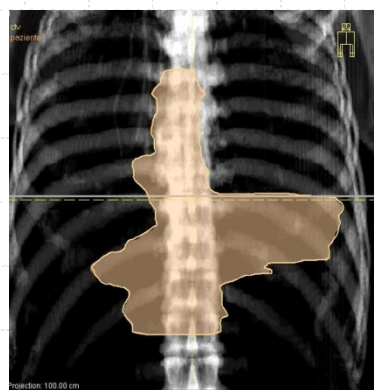
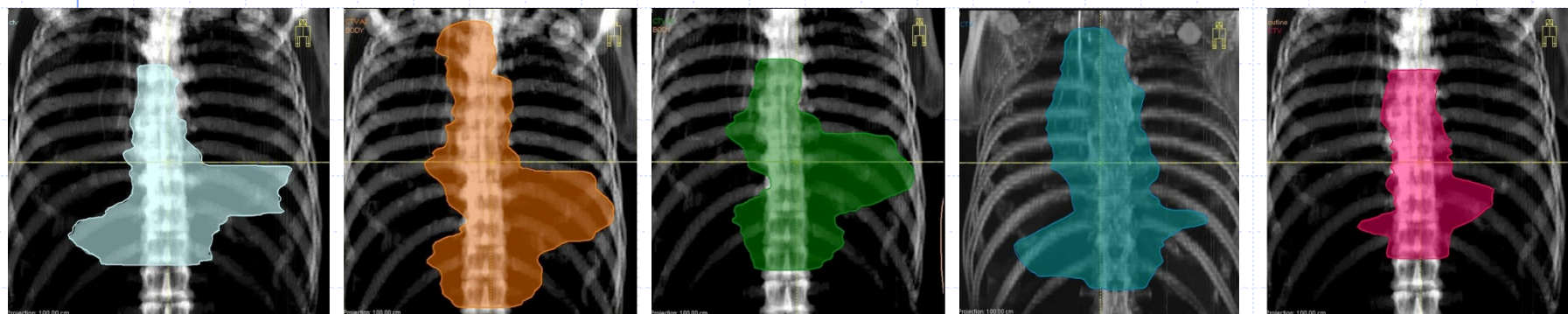
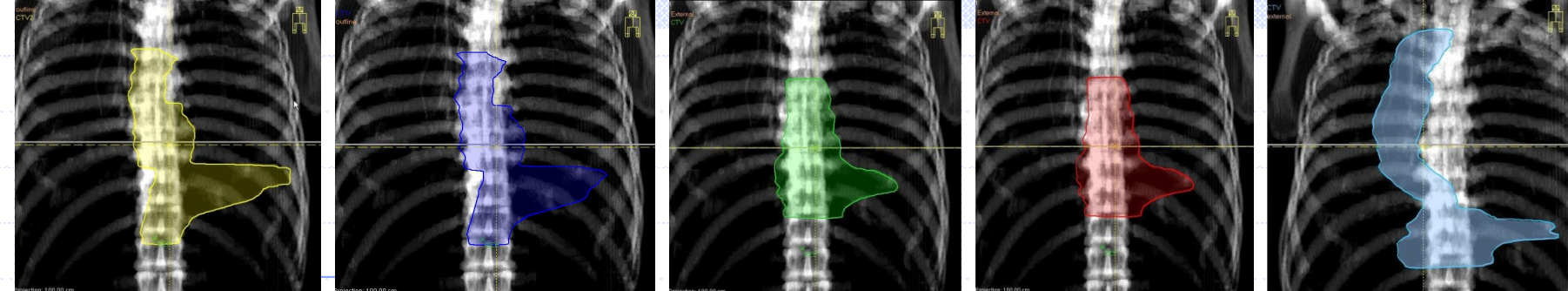
Indicazioni Cliniche e Criteri Guida di Trattamento



COORDINATORI DEL CORSO
A. DE PAOLI, A. GALARDI, V. FUSCO

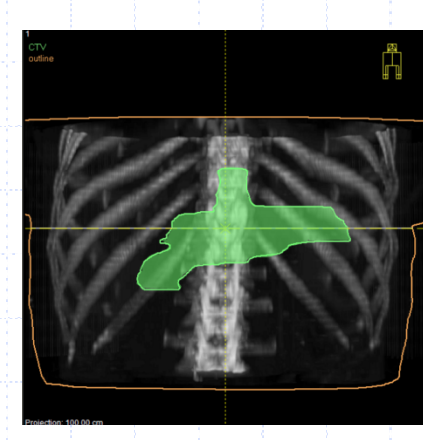
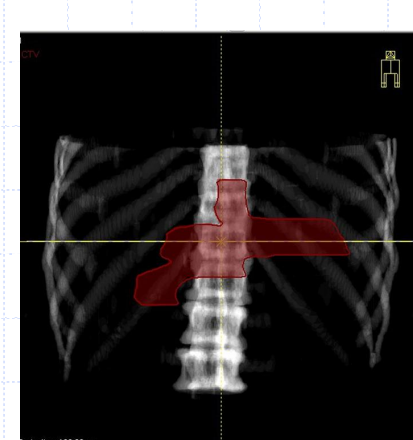
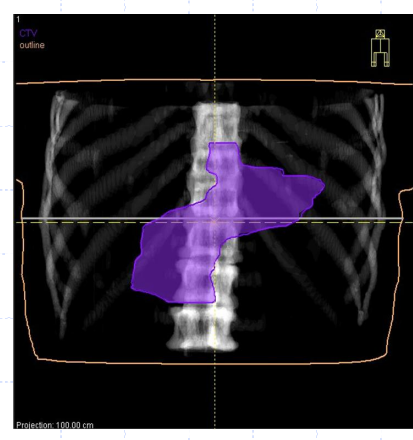
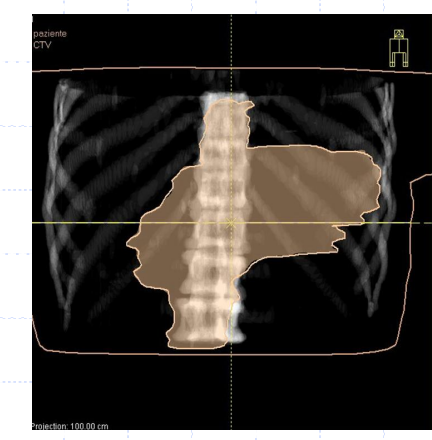
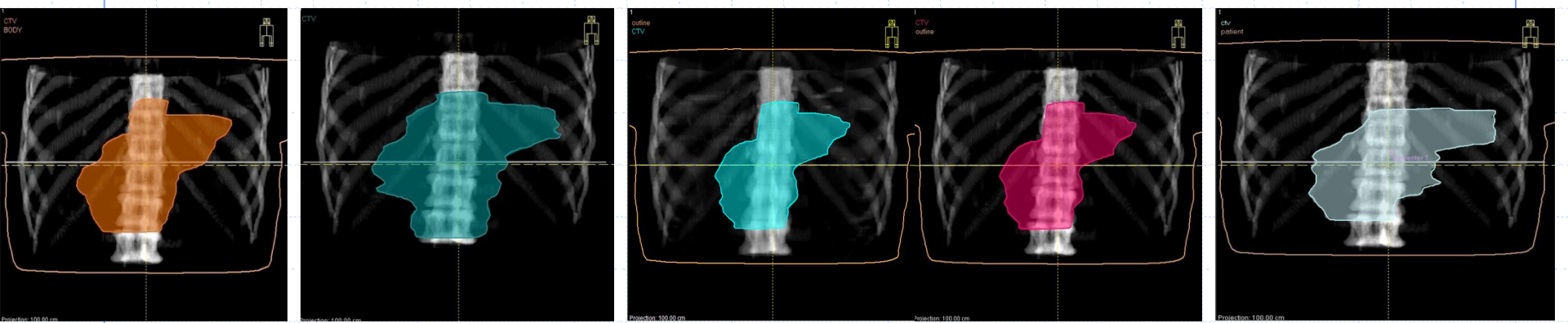
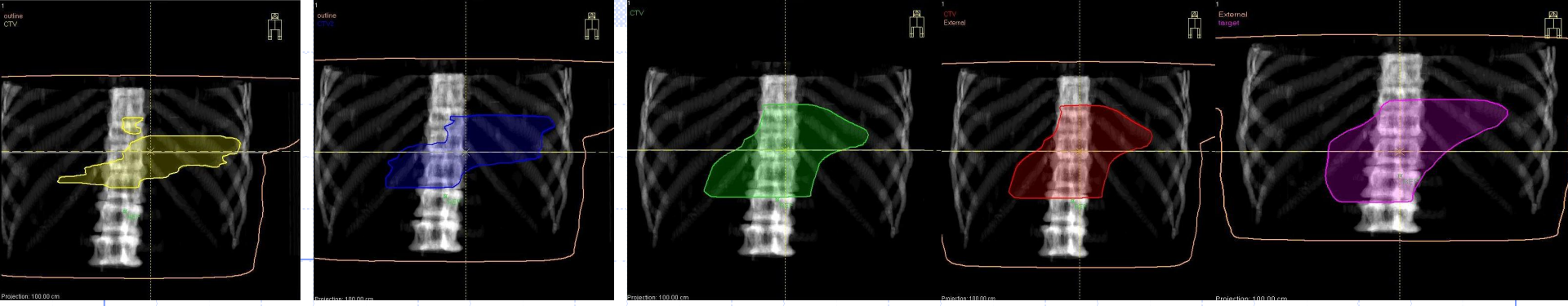
ISTITUTO di RICONVERSO-CUDA e CARATTERE SCIENTIFICO
Centro di Riferimento Oncologico della Basilicata
IRCCS CROG

AVIANO 24 GIUGNO 2011
FIRENZE 28 SETTEMBRE 2011
RIONERO IN VULTURE 20 OTTOBRE 2011



Gastro-Intestinal AIRO Working Group

CASE A



Gastro-Intestinal AIRO Working Group

CASE B

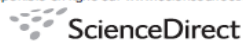Radiation Treatment Parameters in the Adjuvant Postoperative Therapy of Gastric Cancer

Seminars in Radiation Oncology, Vol 12, No 2 (April), 2002: pp 187-195

Joel E. Tepper and Leonard L. Gunderson



Disponible en ligne sur www.sciencedirect.com



Cancer/Radiothérapie 12 (2008) 659–662

Mise au point

Cancer de l'estomac : doses et volumes-cibles

Gastric cancer: Doses and target volumes

C. Hennequin^{a,*}, L. Quero^a, L. Mineur^b

CANCER
RADIOTHÉRAPIE

<http://france.elsevier.com/direct/CANRAD/>

British Journal of Surgery 1995, 82, 346–351

New method to evaluate the therapeutic value of lymph node dissection for gastric cancer

M. SASAKO, P. MCCULLOCH*, T. KINOSHITA† and K. MARUYAMA

Radiotherapy and Oncology 96 (2010) 223–230



ELSEVIER

Contents lists available at ScienceDirect

Radiotherapy and Oncology

journal homepage: www.thegreenjournal.com



Gastric carcinoma

Pattern of lymph node metastases and its implication in radiotherapeutic clinical target volume delineation of regional lymph node in patients with gastric carcinoma ☆

Yan Yi, Jinming Yu, Baosheng Li *, Fujun Yang, Wei Huang, Hongfu Sun, Heyi Gong, Tao Zhou, Haiqun Lin

Department of Radiation Oncology, Shandong Cancer Hospital and Institute, Jinan, PR China

NCCN

National
Comprehensive
Cancer
Network.®

**NCCN Guidelines™ Version 2.2011
Gastric Cancer**

Radiation Treatment Parameters in the Adjuvant Postoperative Therapy of Gastric Cancer

Joel E. Tepper and Leonard L. Gunderson

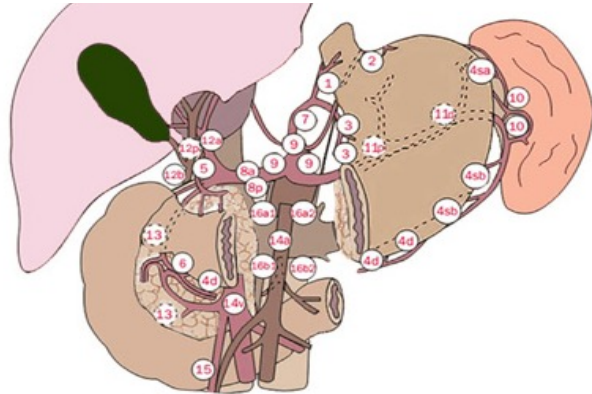
Table 6. Impact of Site of Primary Gastric Lesion and TN Stage on Irradiation Treatment Volumes—Antrum/Pylorus/Distal One Third of Stomach (General Guidelines)

<i>Site of Primary and TN Stage</i>	<i>Remaining Stomach</i>	<i>Tumor Bed Volumes**</i>	<i>Nodal Volumes</i>	<i>Tolerance Organ Structures</i>
4) Pylorus/distal 1/3 stomach T2N0 with invasion of subserosa	Yes, but spare 2/3 of one kidney (usually L) Variable dependent on surgical-pathologic findings*	T-stage dependent Head of pancreas, (+/- body), 1st and 2nd duodenum	N-stage dependent None or perigastric; optional: pancreaticoduodenal, porta hepatis, celiac, supra-pancreatic***	Kidneys, liver, spinal cord
T3N0	Variable dependent on surgical-pathologic findings*	Head of pancreas, (+/- body), 1st and 2nd duodenum	None or perigastric; optional: pancreaticoduodenal, porta hepatis, celiac, supra-pancreatic***	
T4N0	Preferable but dependent on surgical-pathologic findings*	As for T3N0 plus site(s) of adherence with 3-5 cm margin	Nodes related to site(s) of adherence +/- perigastric, pancreaticoduodenal, portahepatis, celiac, supra-panc	
T1-2N+	Preferable	Not indicated for T1	Perigastric, pancreaticoduodenal, portahepatis, celiac, supra-pancreatic; Optional splenic hilum***	
T3-4N+	Preferable	As for T3, T4N0	As for T1-2N+ and T4N0	

*For tumors with wide (>5 cm) surgical margins confirmed pathologically, treatment of residual stomach is optional if this would result in substantial increase in normal tissue morbidity.

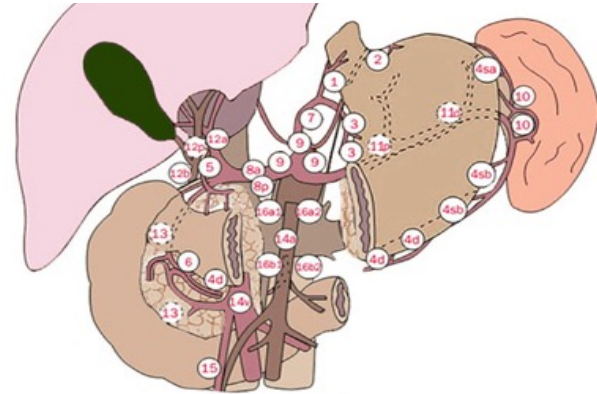
**Use preop imaging (CT, barium swallow), surgical clips, and postop imaging (CT, barium swallow).

***Optional node inclusion for T2-3N0 lesions if there has been an adequate surgical node dissection (D2 dissection) and at least 10-15 nodes have been examined pathologically.

A**UPPER GASTRIC CANCER**

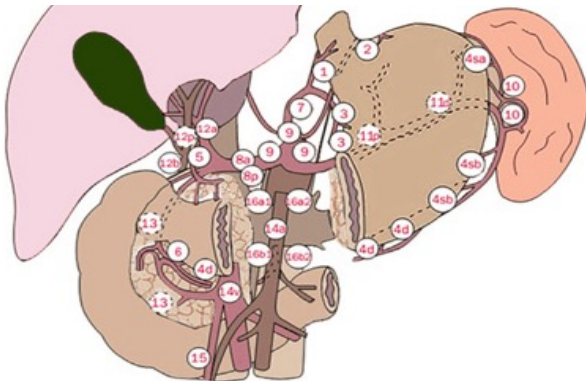
1,2,3,4, 5, 6,7, 8, 9,10,11,12

① 61.7%/35.33	② 25.0%/4.6	③ 71.3%/41.7	④ 46.3%/37.3
⑤ 0/0	⑥ 13.3%/4.7	⑦ 38.9%/34.2	⑧ 5.0%/1.3
⑨ 15.4%/19.5	⑩ 25.0%/7.7	⑪ 37.5%/26.7	⑫ 20.0%/9.1
⑬ 0/0	⑭ 0/0	⑮ 0/0	⑯ 0/0

B**MIDDLE GASTRIC CANCER**

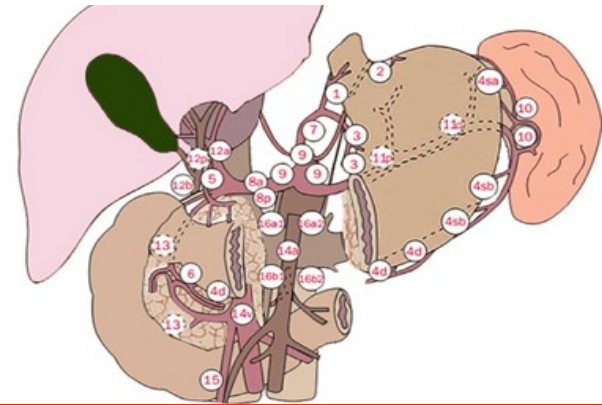1,2,3,4,5,6,7,8,9,10,11,12,13, 14

① 31.3%/24.4%	② 28.6%/35.7%	③ 74.5%/43.1%	④ 49.5%/35.1%
⑤ 40.0%/36.4%	⑥ 29.4%/28.3%	⑦ 29.0%/25.7%	⑧ 33.3%/19.7%
⑨ 23.1%/13.4%	⑩ 20.0%/25.0%	⑪ 30.0%/16.1%	⑫ 21.4%/16.1%
⑬ 20.0%/16.7%	⑭ 7.1%/12.1%	⑮ 0/0	⑯ 0/0

LOWER-MIDDLE GASTRIC CANCER

1,2,3,4,5,6,7,8,9,10,11,12,13, 14, 15,16

① 21.1%/23.5%	② 33.3%/10.0%	③ 52.7%/29.8%	④ 46.8%/30.5%
⑤ 43.5%/37.6%	⑥ 47.4%/24.1%	⑦ 21.2%/12.0%	⑧ 27.2%/14.6%
⑨ 14.5%/11.2%	⑩ 0/0	⑪ 16.2%/10.1%	⑫ 18.8%/13.4%
⑬ 11.1%/10.5%	⑭ 6.7%/2.9%	⑮ 25.0%/20.0%	⑯ 20.0%/18.2%

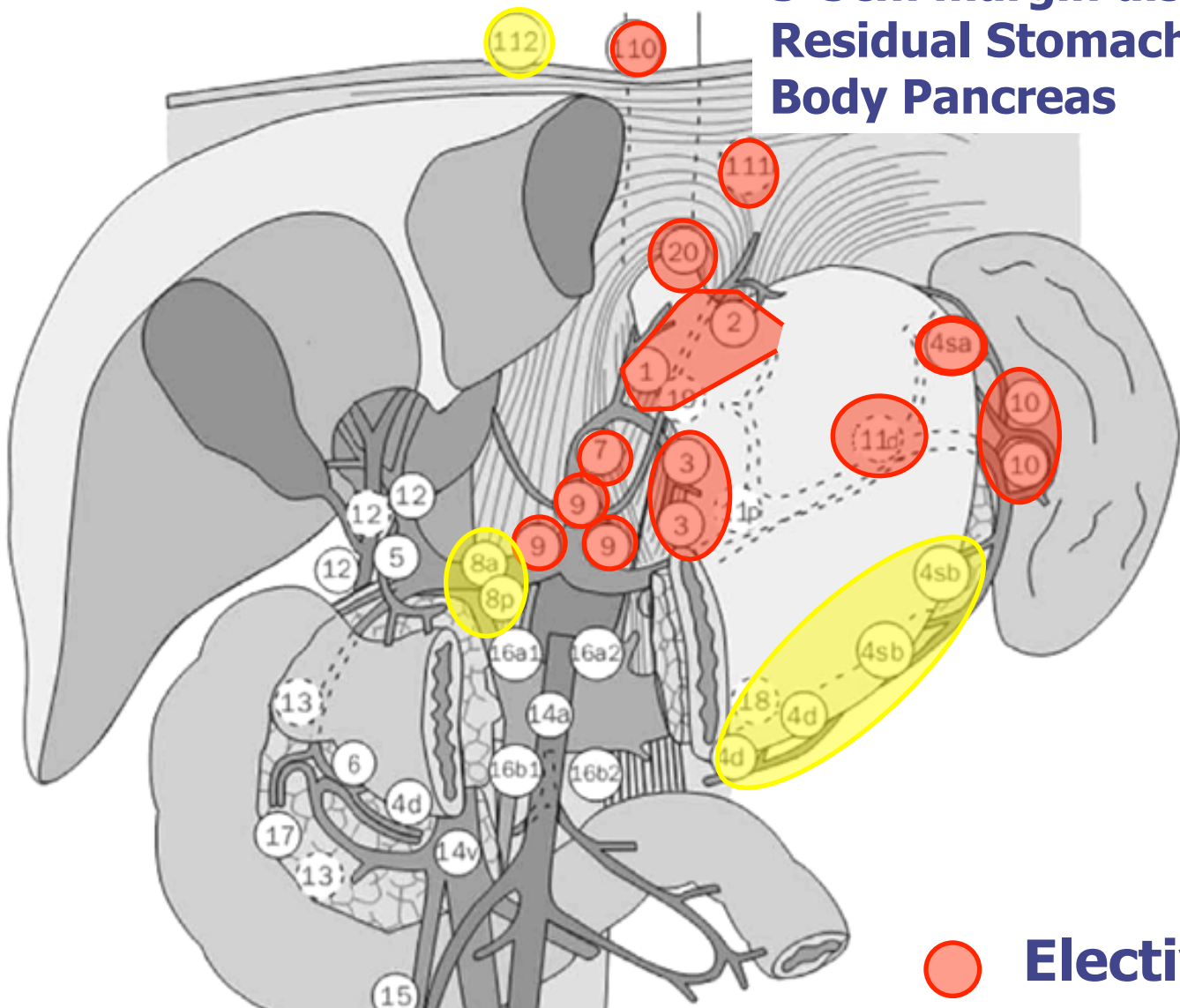
LOWER-WHOLE GASTRIC CANCER

3,4,5,6,7,8, 9, 10,11,12,13, 14, 15, 16

① 0/0	② 0/0	③ 85.2%/67.3%	④ 81.5%/43.9%
⑤ 60.0%/28.6%	⑥ 50.0%/20.0%	⑦ 66.7%/83.3%	⑧ 20.0%/8.3%
⑨ 0/0	⑩ 0/0	⑪ 66.7%/71.4%	⑫ 0/0
⑬ 66.7%/55.6%	⑭ 0/0	⑮ 0/0	⑯ 0/0

EG JUNCTION

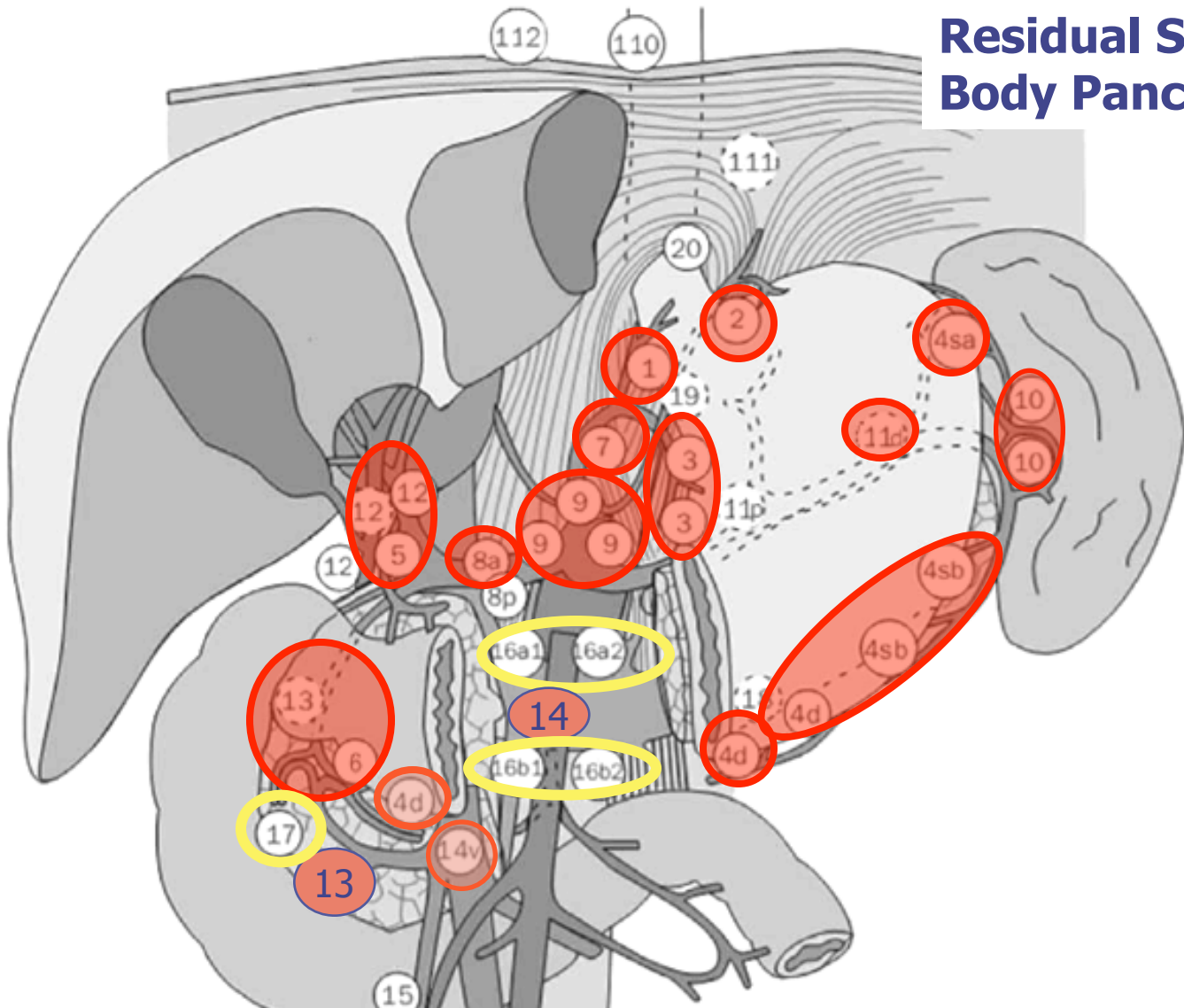
CTV/primary:
3-5cm margin distal esoph
Residual Stomach/Anastom
Body Pancreas



- Elective**
- Low risk**

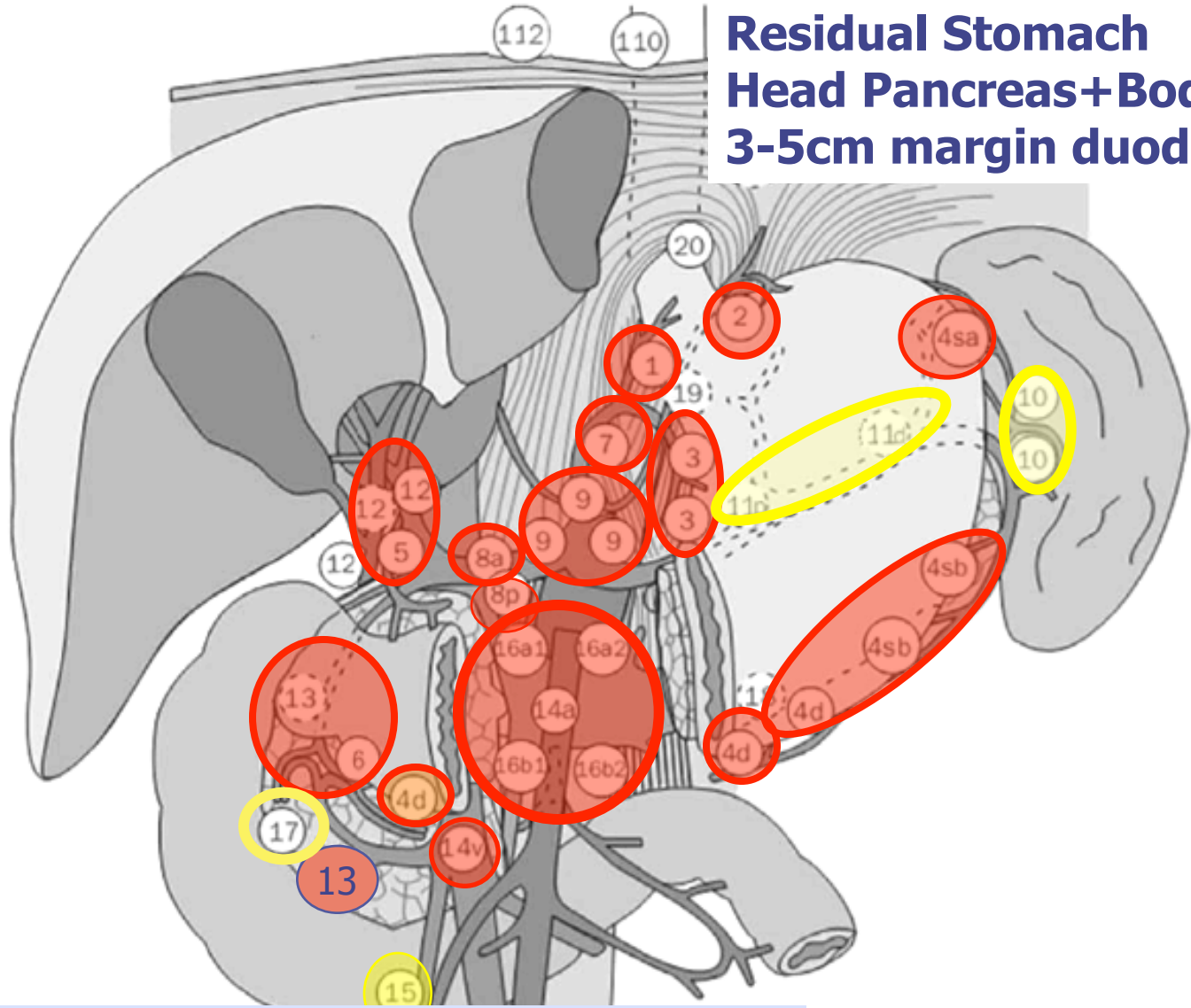
Middle One Third

CTV/primary:
Anastomosis
Residual Stomach
Body Pancreas+Tail



Distal One Third

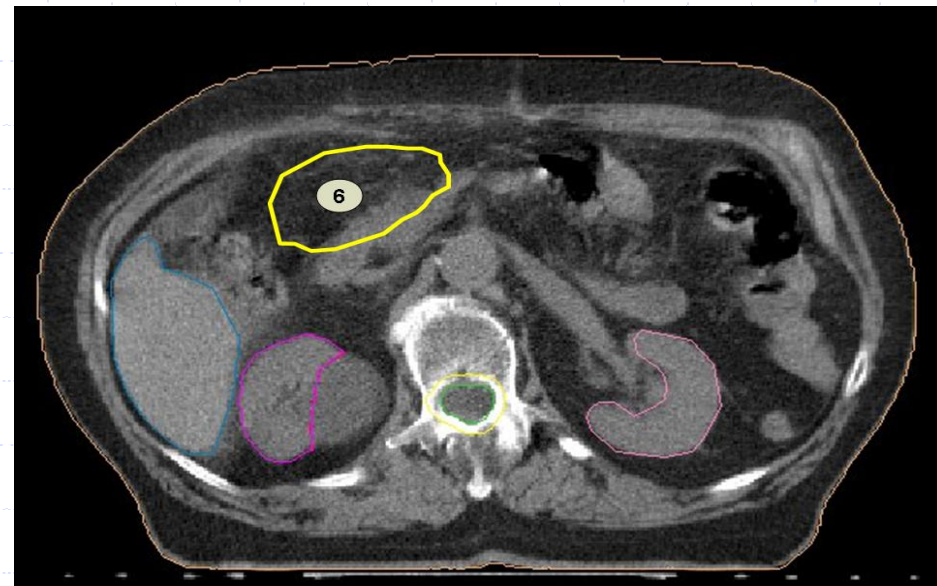
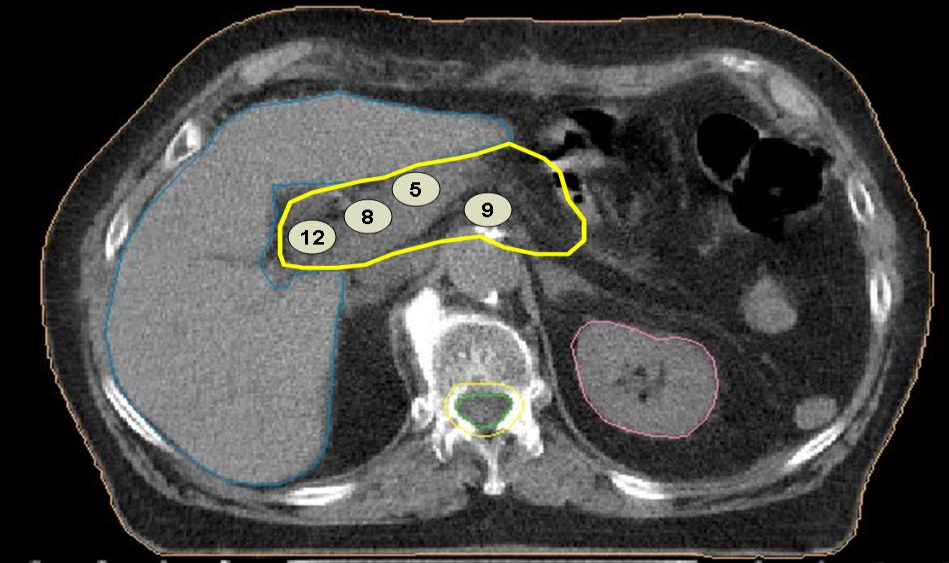
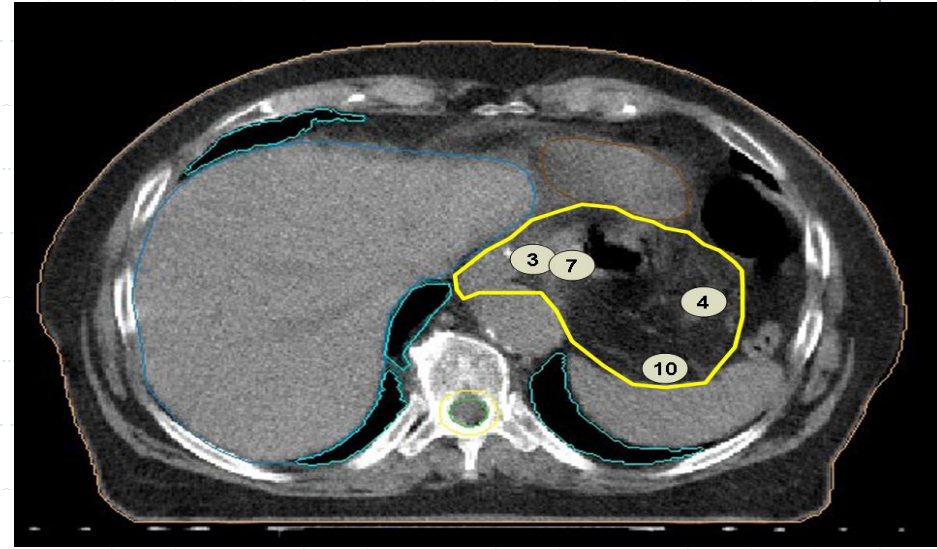
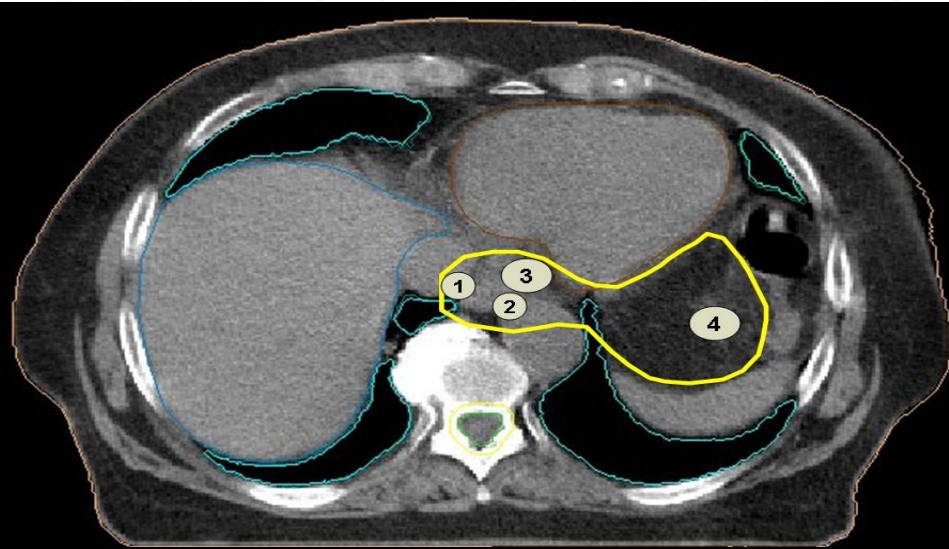
CTV/primary:
Anastomosis
Residual Stomach
Head Pancreas+Body
3-5cm margin duoden. stump



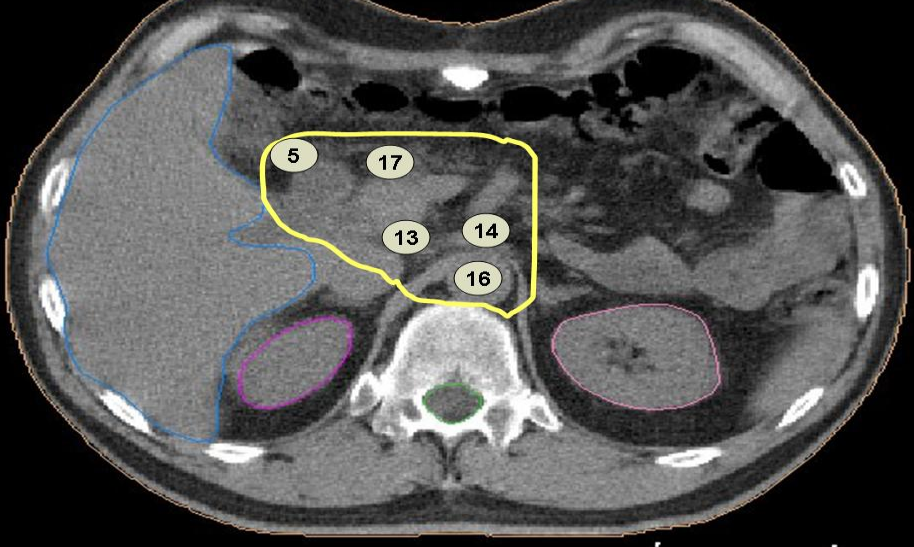
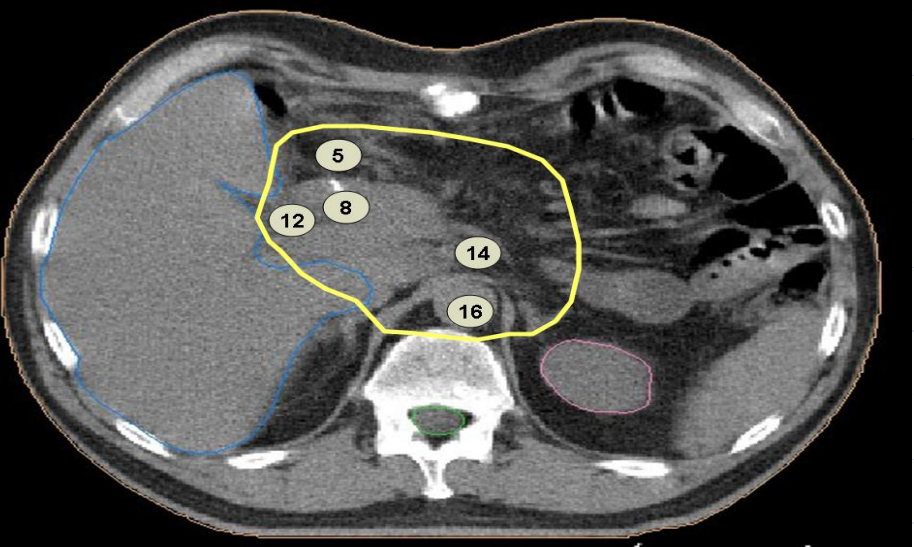
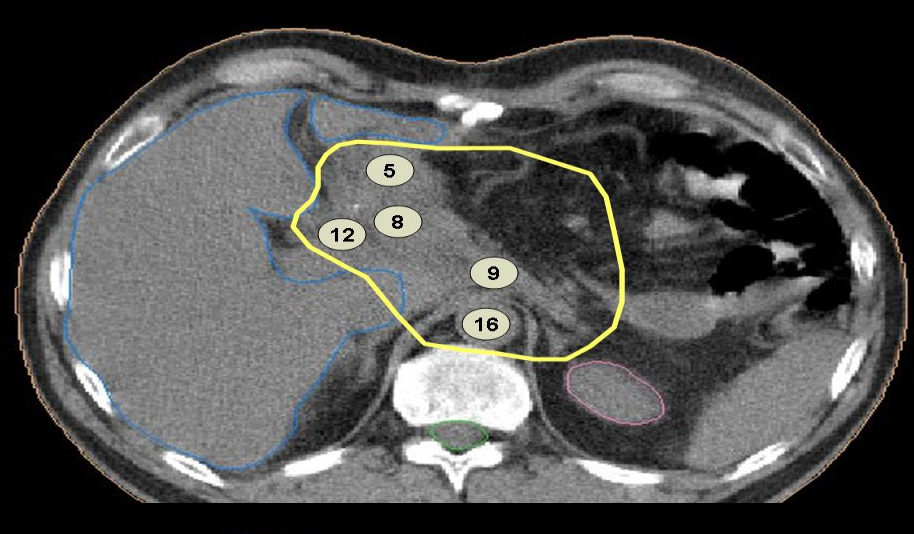
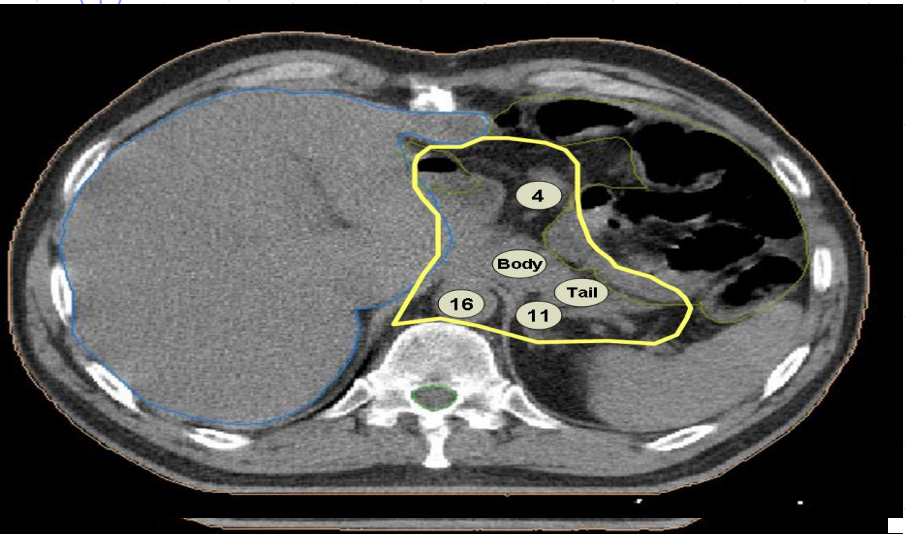
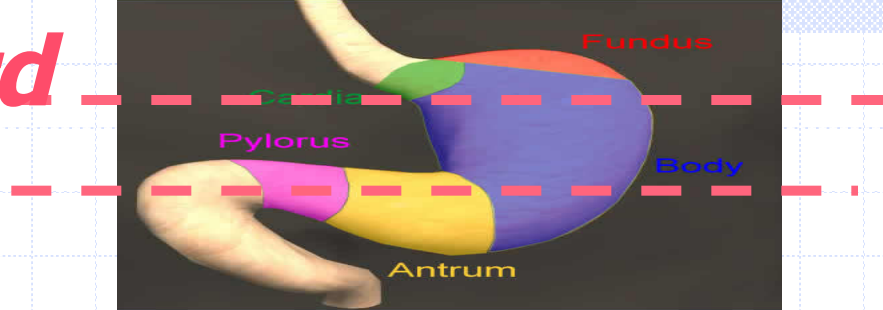


***Postoperative Anatomic
findings
at CT following
Gastrectomy***

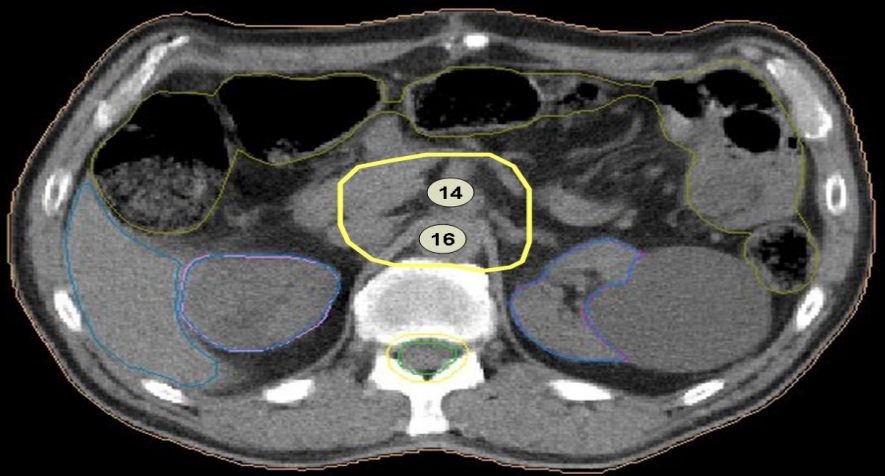
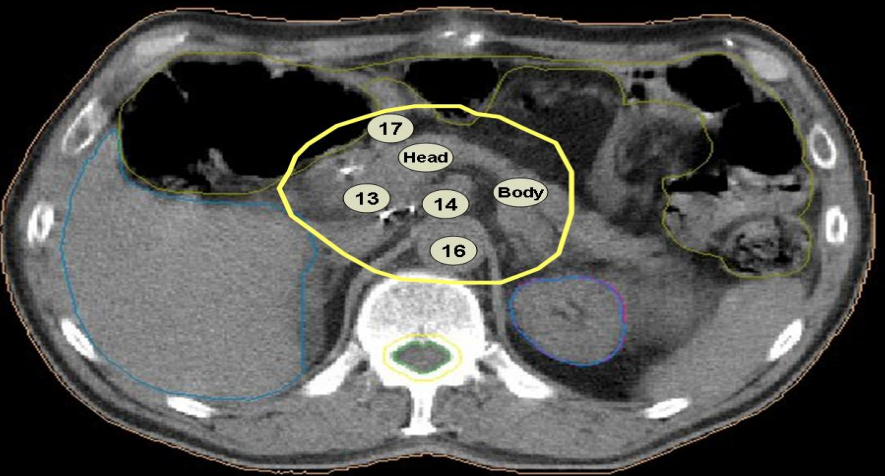
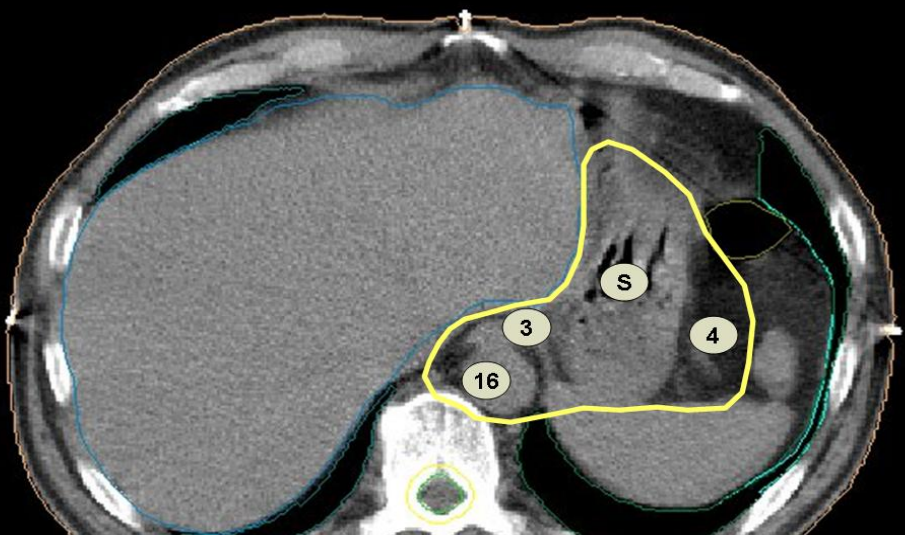
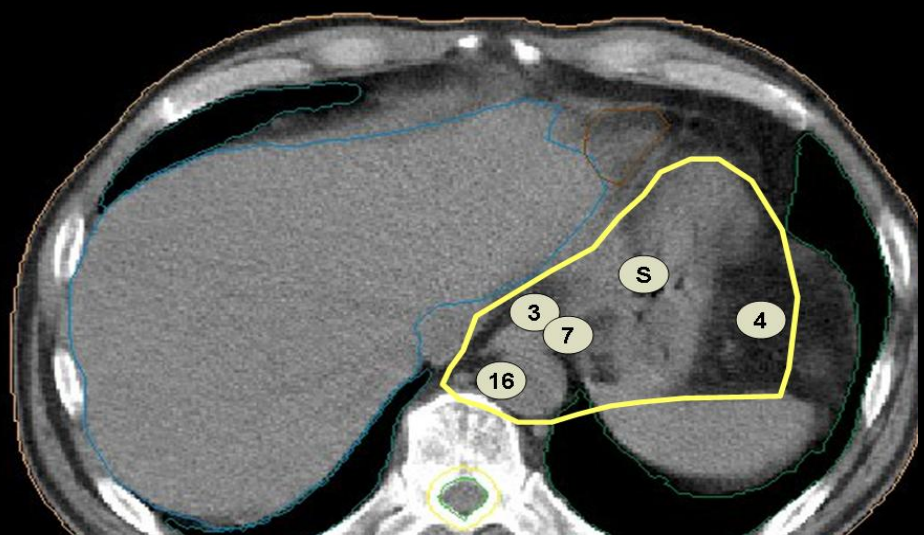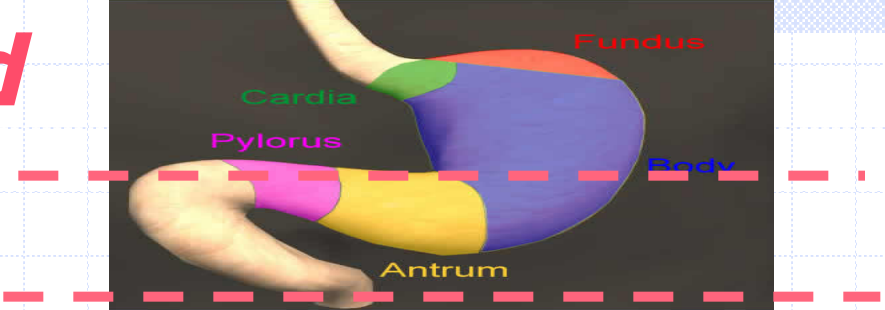
Upper 3rd



Middle 3rd



Lower 3rd



Postoperative Anatomic and Pathologic Findings at CT Following Gastrectomy¹

Kyoung Won Kim,

2002

LEARNING OBJECTIVES

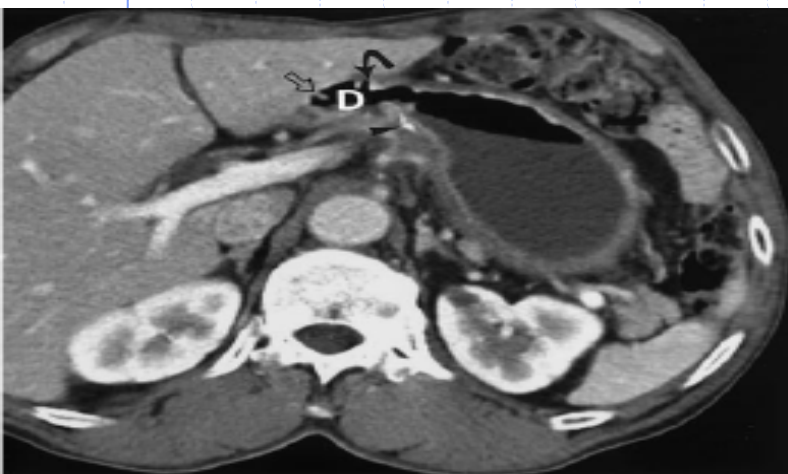After reading this article and taking the test, the reader will be able to:

- Discuss optimal CT technique for evaluation of patients who have undergone gastrectomy.
- Describe the CT appearance of postoperative changes following gastrectomy.
- Discuss the various patterns of postoperative complications and tumor recurrence in affected patients.

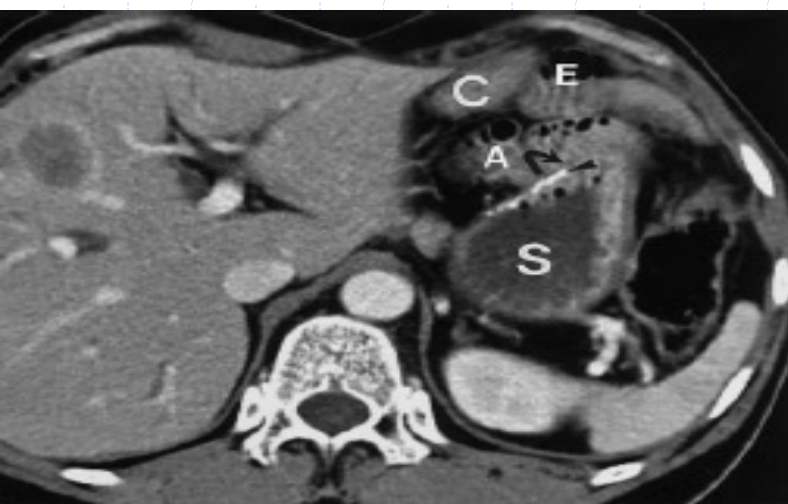Postoperative Anatomic and Pathologic Findings at CT Following Gastrectomy¹

Kyoung Won Kim

2002



Billroth I Gastroduodenostomy

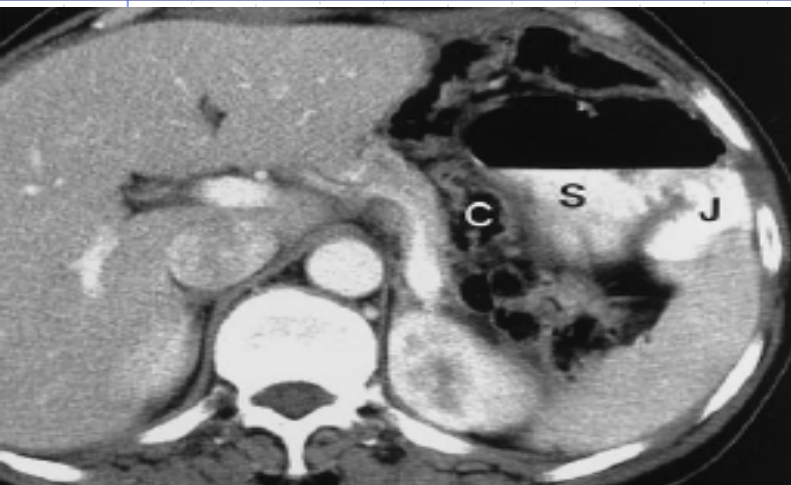


Billroth II Gastrojejunostomy Retrocolic

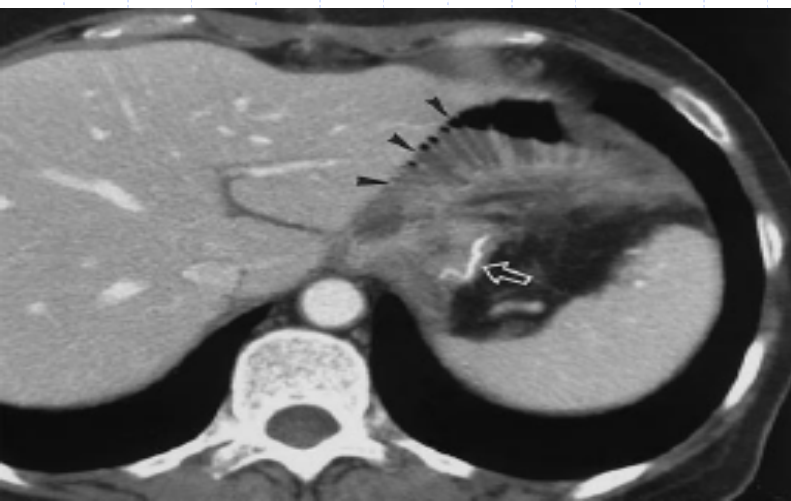
Postoperative Anatomic and Pathologic Findings at CT Following Gastrectomy¹

Kyoung Won Kim

2002



***Billroth II Gastrojejunostomy
Anterior to the transverse colon***



***Total Gastrectomy with
esophagojejunostomy***

CT PLANNING: rules

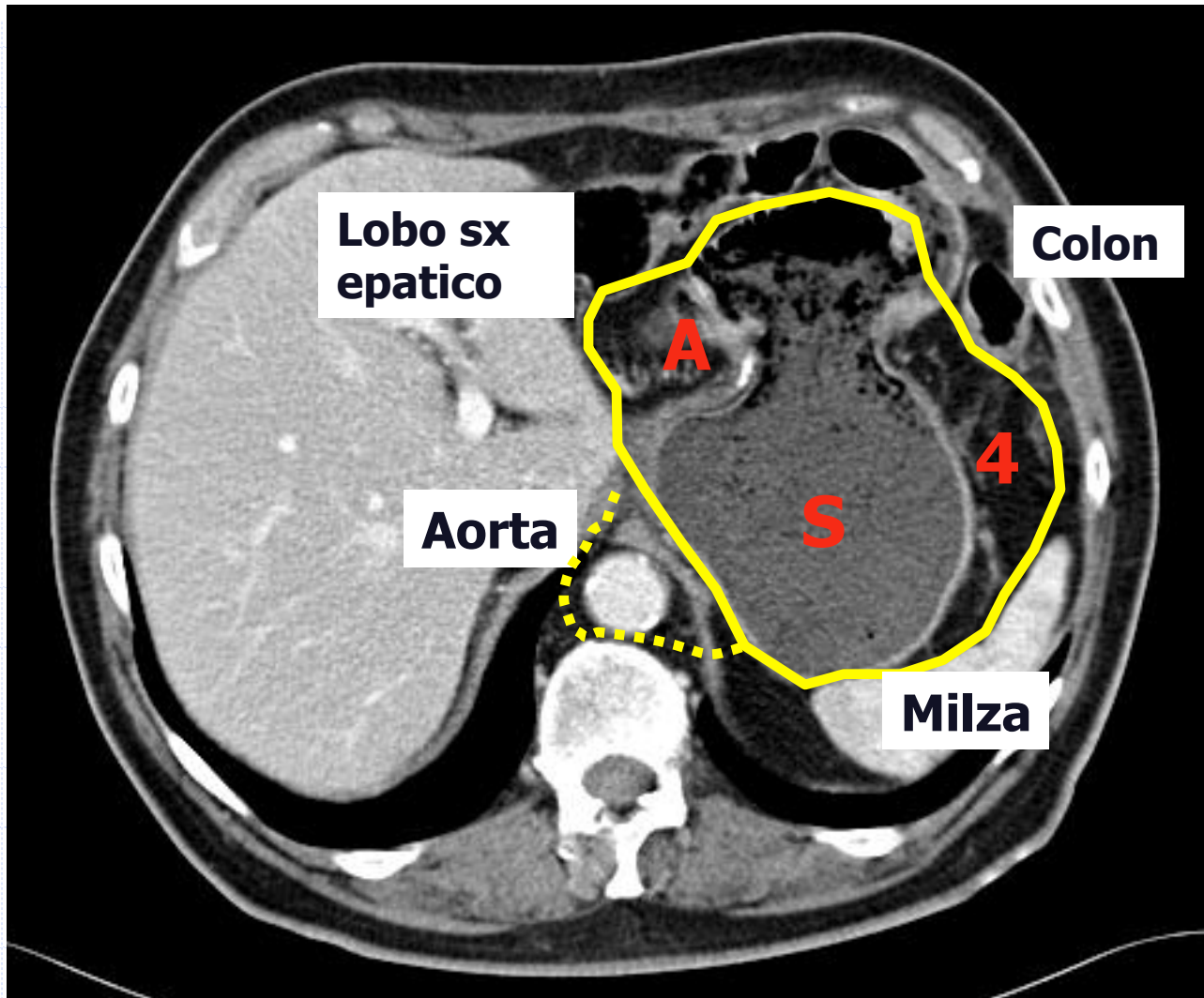
- ❖ Radiologist-based Team for Planning:
anatom/radiological boundaries
- ❖ **NO Coregistration CT pre & post Surg & SIM-CT**
- ❖ **Empty Stomach**
No heavy meal 3 hours before SIM-CT

ANTRUM: subtotal Gastrectomy

Billroth II Gastrojejunostomy

Retrocolic

CTVs Boundaries

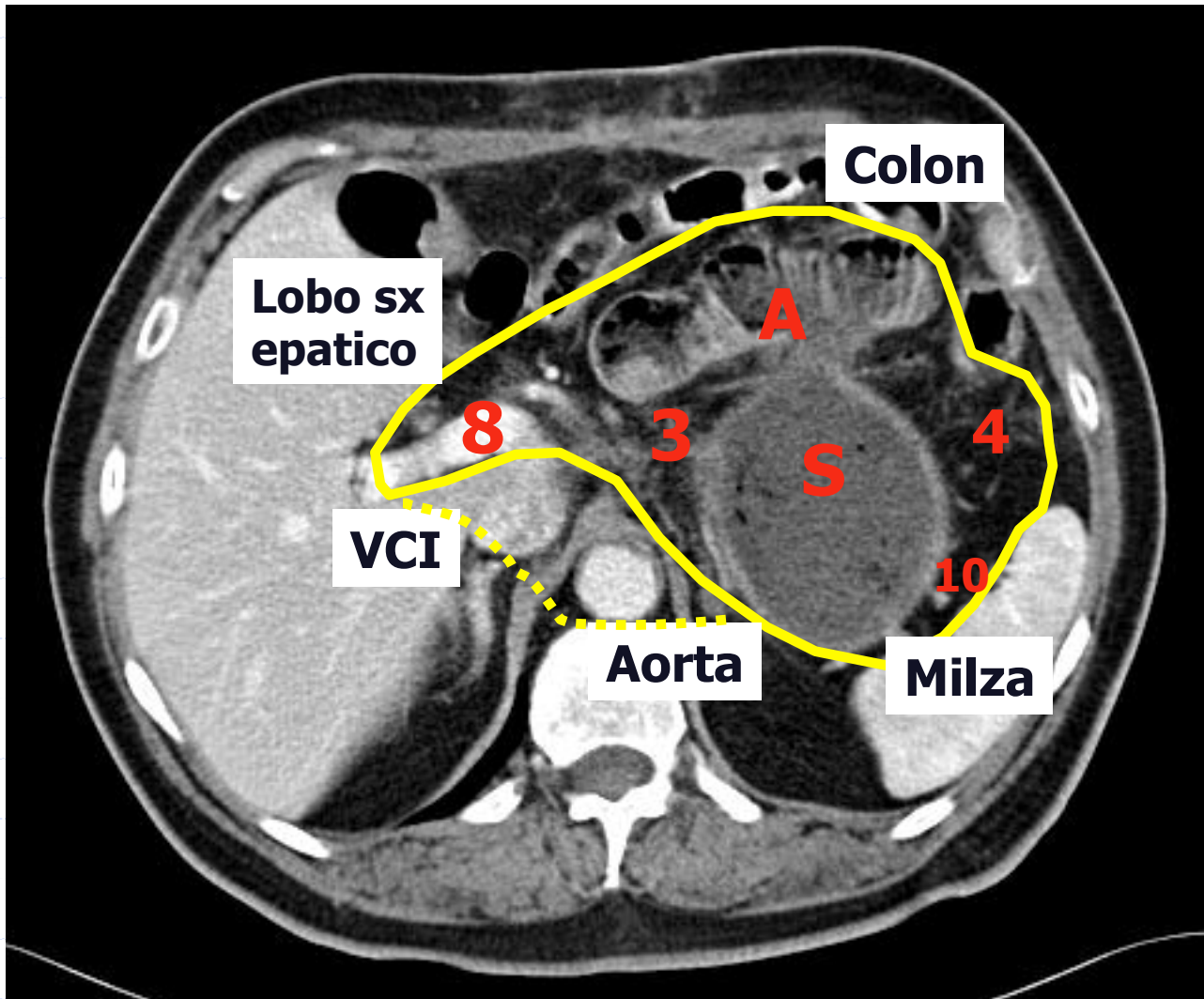


ANTRUM: subtotal Gastrectomy

Billroth II Gastrojejunostomy

Retrocolic

CTVs Boundaries

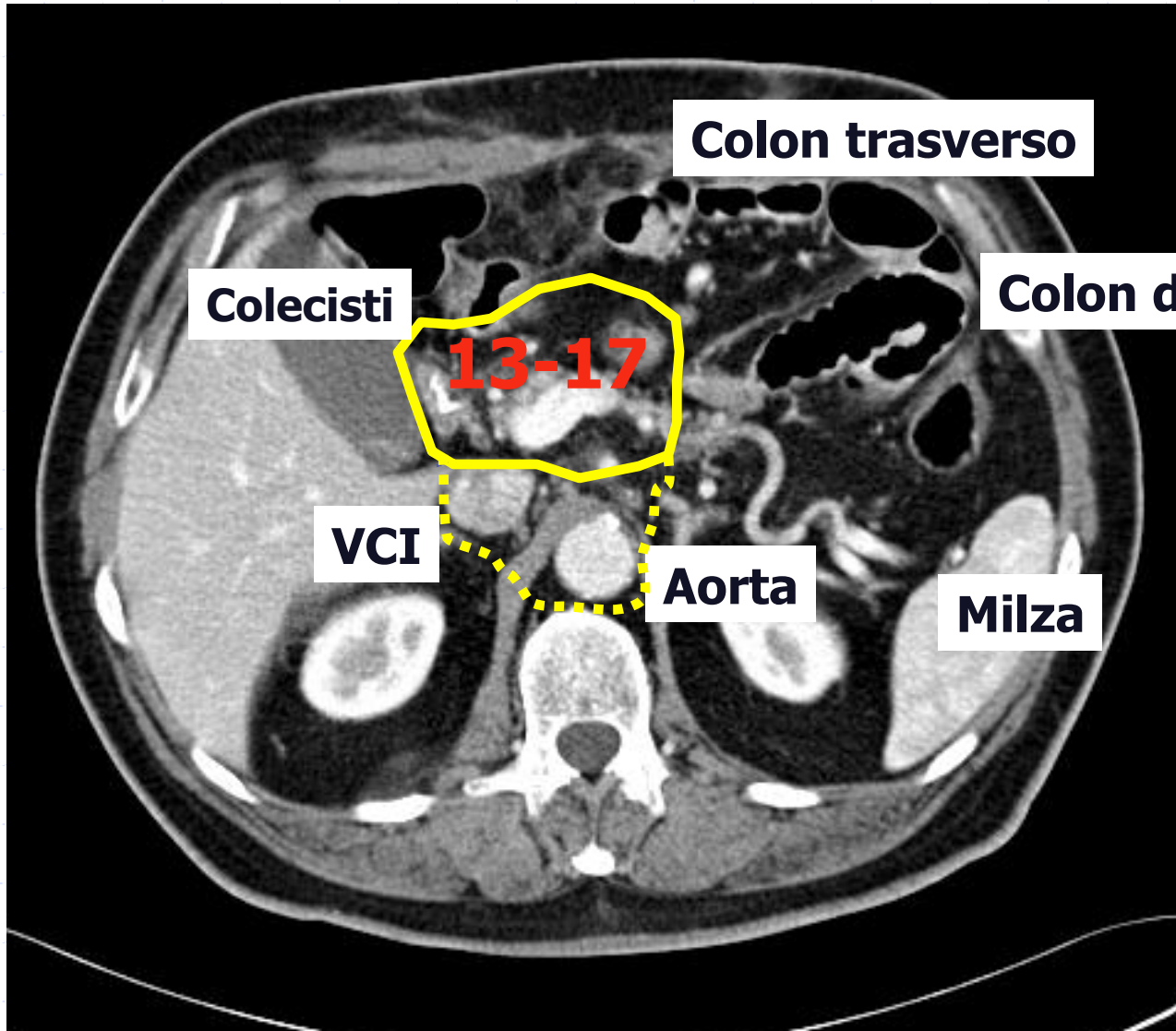


ANTRUM: subtotal Gastrectomy

Billroth II Gastrojejunostomy

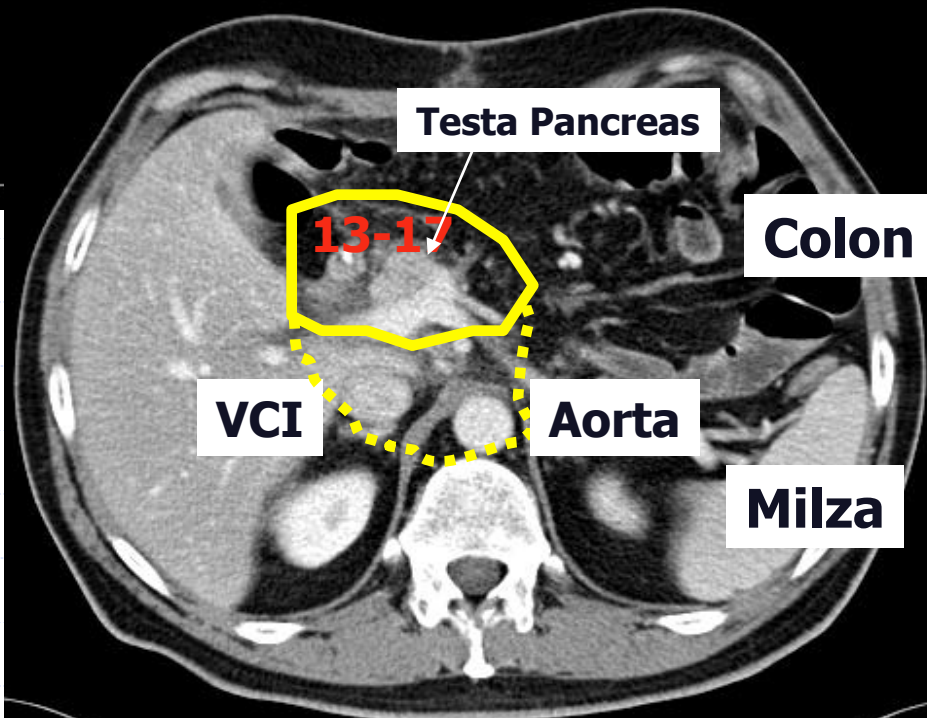
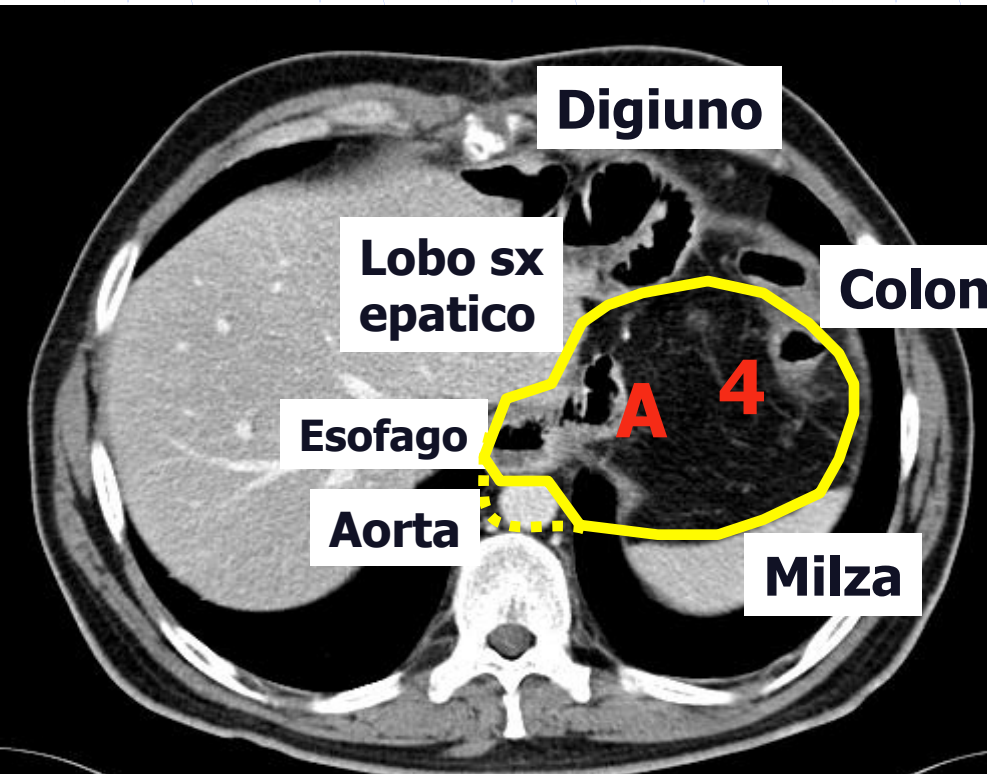
Retrocolic

CTVs Boundaries



ANTRUM: total Gastrectomy

CTVs Boundaries



Clinical Target Volumes


- *preoperative setting*
- *CTVs/Tumor site*



Contents lists available at ScienceDirect

Radiotherapy and Oncology

journal homepage: www.thegreenjournal.com



Guidelines

EORTC guidelines

EORTC-ROG expert opinion: Radiotherapy volume and treatment guidelines for neoadjuvant radiation of adenocarcinomas of the gastroesophageal junction and the stomach

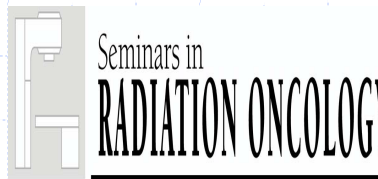
Oscar Matzinger^{a,b,*}, Erich Gerber^c, Zvi Bernstein^d, Philippe Maingon^e, Karin Haustermans^f, Jean François Bosset^g, Akos Gulyban^a, Philip Poortmans^h, Laurence Collette^a, Abraham Kuten^d

GTV

CTV

PTV

TOOLS for CTVs in Preop setting



Rafael Martinez-Monge, MD
Patrick S. Fernandes, MD
Nilendu Gupta, PhD
Reinhard Gahbauer, MD

Cross-sectional Nodal Atlas: A Tool for the Definition of Clinical Target Volumes in Three-dimensional Radiation Therapy Planning¹

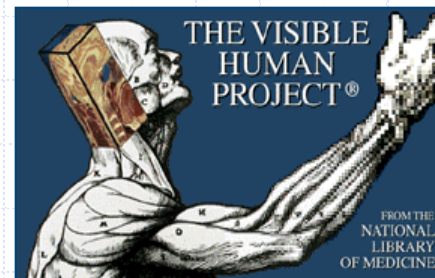
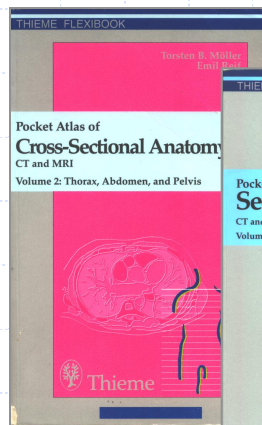
Index terms:
Computed tomography (CT),
three-dimensional, 99.12917, 99.92
Lymphatic system, 99.12917, 99.92
Special reports
Treatment planning, 99.92

Radiology 1999; 211:815-828

Abbreviations:
CTV = clinical target volume
GTV = gross tumor volume
3D = three-dimensional

Virtual three-dimensional clinical target volume definition requires the identification of areas suspected of containing microscopic disease (frequently related to nodal stations) on a set of computed tomographic (CT) images, rather than the traditional approach based on anatomic landmarks. This atlas displays the clinically relevant nodal stations and their correlation with normal lymphatic pathways on a set of CT images.

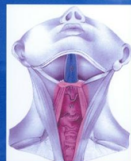
¹ From the Division of Radiation Oncology, The Arthur G. James Cancer Hospital, Ohio State University, 300 W. Tenth Ave., Columbus, OH 43230. Received Oct 10, 2002.



Clinical Target Volumes in Conformal and Intensity Modulated Radiation Therapy

A Clinical Guide to Cancer Treatment

V. Grégoire
P. Scalliet
K.K. Ang
Editors



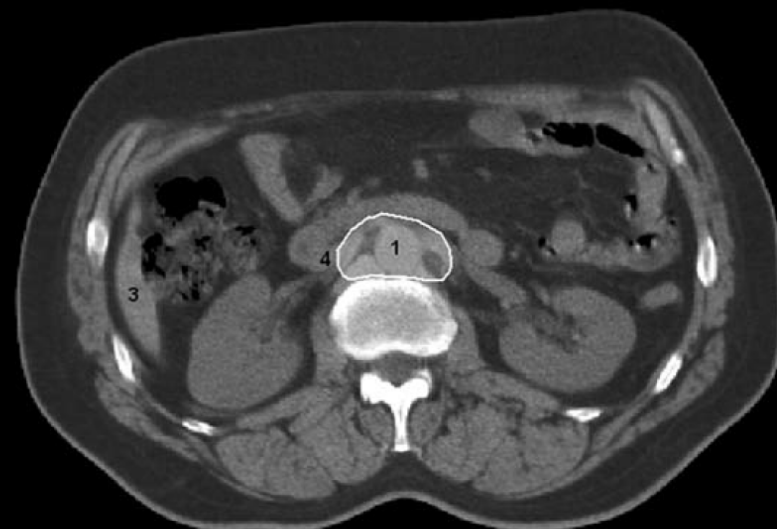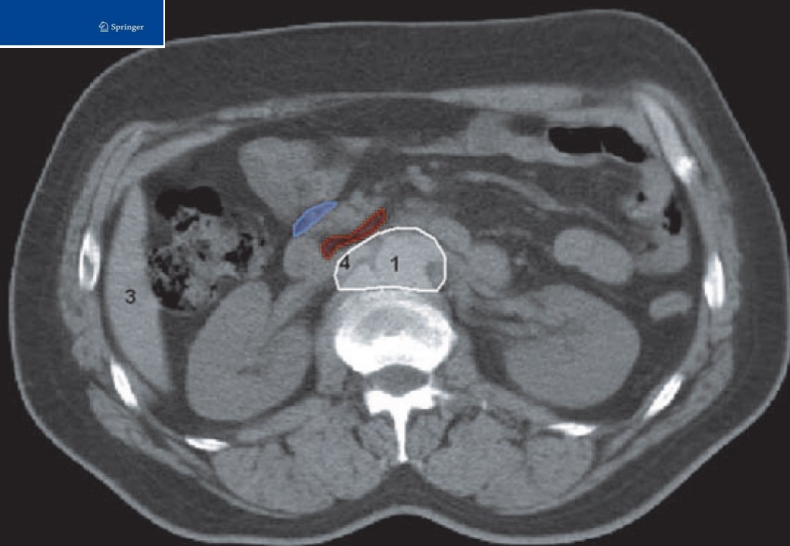
Preoperative radiotherapy in gastric cancer: CTV definition for conformal therapy according to tumor location

Cellini F, Valentini V, Pacelli F, D'Ugo D,
Mantini G, Balducci M, Gambacorta MA,
Nori S

Rays. 2003 Jul-Sep;28(3):317-29

A Guide for Delineation of Lymph Nodal Clinical Target Volume in Radiation Therapy





■ POSTERIOR PANCREATICODUODENAL NODES

(13)

■ NODES AROUND THE ABDOMINAL AORTA

(16)

■ ANTERIOR PANCREATICODUODENAL NODES

(17)

1 - DESCENDING AORTA

3 - LIVER

4 - INFERIOR VENA CAVA

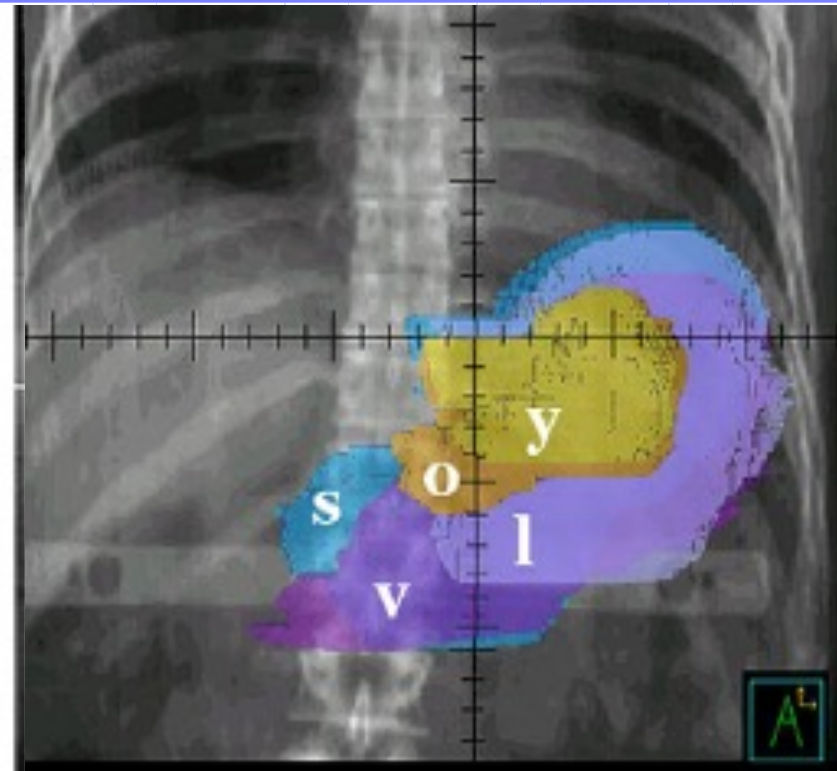
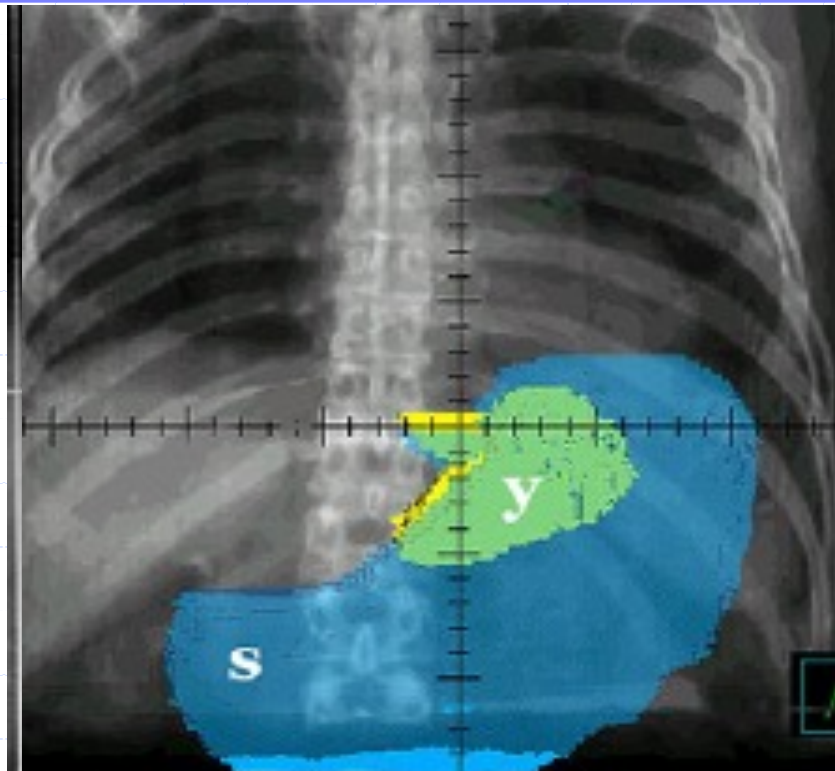
doi:10.1016/j.ijrobp.2009.08.026

PHYSICS CONTRIBUTION

**IMPACT OF GASTRIC FILLING ON RADIATION DOSE DELIVERED TO
GASTROESOPHAGEAL JUNCTION TUMORS**

MYRIAM BOUCHARD, M.D.,* MARY FRANCES MCALEER, M.D., PH.D.,[†]
AND GEORGE STARKSCHALL, PH.D.*

Departments of *Radiation Physics and [†]Radiation Oncology, The University of Texas M. D. Anderson Cancer Center, Houston, TX

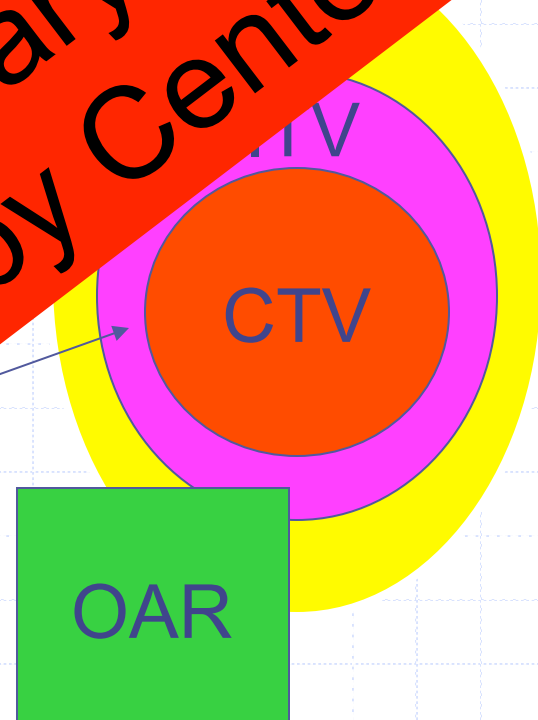


PTV

SET UP ERROR MARGIN


RT

INT



Margin is necessary !!
Performed Center by Center !!

SET UP ERROR interfraction
ORGAN MOTION interfraction
ORGAN MOTION intrafraction



Guidelines

EORTC-ROG expert opinion: Radiotherapy volume and treatment guidelines for neoadjuvant radiation of adenocarcinomas of the gastroesophageal junction and the stomach

Oscar Matzinger^{a,b,*}, Erich Gerber^c, Zvi Bernstein^d, Philippe Maingon^e, Karin Haustermans^f, Jean François Bosset^g, Akos Gulyban^a, Philip Poortmans^h, Laurence Collette^a, Abraham Kuten^d

Organ at risk (OARs) volumes

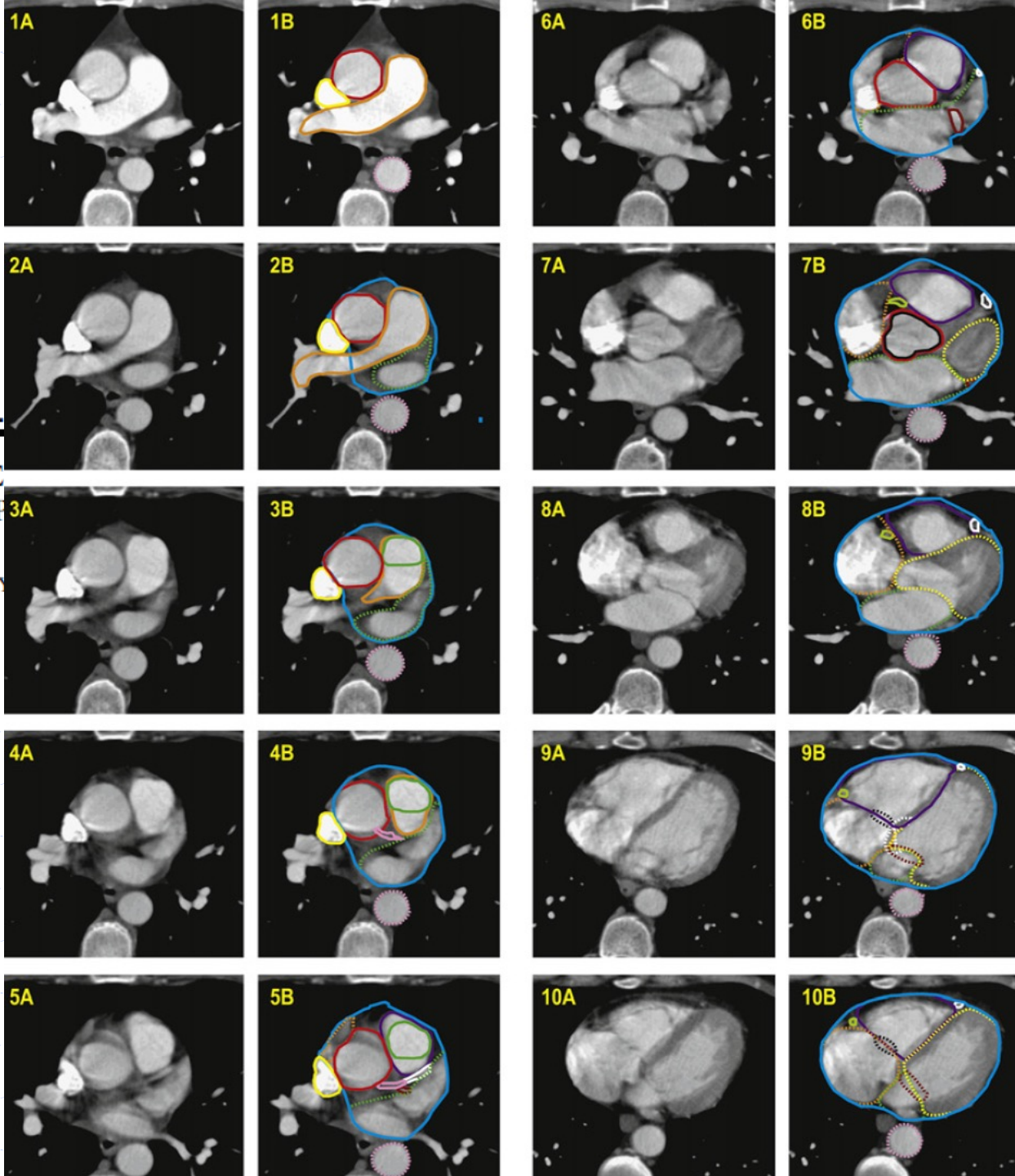
- lungs,
- liver,
- kidneys
- Heart
- Spinal cord

◆ Spinal cord must be outlined along the whole volume interested by the beams + 2 cm above or below this volume



CLINICAL

DE
EXI
MARY



79, No. 1, pp. 10–18, 2011
Copyright © 2011 Elsevier Inc.
the USA. All rights reserved
360-3016/S—see front matter

Breast

**CARDIAC
CANCER**

ITAI, M.D.,[†]

*
D.,*
*

KEY

- Heart ———
- Right atrium ———
- Left atrium ———
- Right ventricle ———
- Left ventricle ———
- Pulmonary artery ———
- Superior vena cava ———
- Descending aorta ———
- Ascending aorta ———
- Aortic valve ———
- Pulmonic valve ———
- Mitral valve ———
- Tricuspid valve ———
- Left main coronary artery ———
- Left anterior descending artery ———
- Left circumflex ———
- Right coronary artery ———
- AV node ———

Conclusions

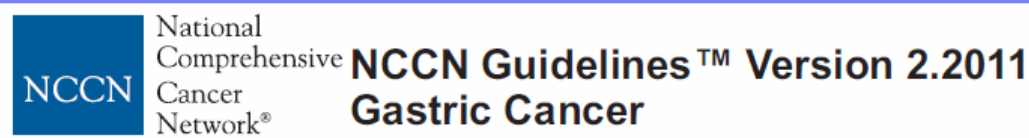
Joel E. Tepper and Leonard L. Gunderson

Seminars in Radiation Oncology, Vol 12, No 2 (April), 2002: pp 187-195



Radiotherapy and Oncology 96 (2010) 223–230
Contents lists available at ScienceDirect
Radiotherapy and Oncology
journal homepage: www.thegreenjournal.com

Gastric carcinoma
Pattern of lymph node metastases and its implication in radiotherapeutic clinical target volume delineation of regional lymph node in patients with gastric carcinoma [☆]
Yan Yi, Jinming Yu, Baosheng Li ^{*}, Fujun Yang, Wei Huang, Hongfu Sun, Heyi Gong, Tao Zhou, Haiqun Lin
Department of Radiation Oncology, Shandong Cancer Hospital and Institute, Jinan, PR China




NCCN National Comprehensive Cancer Network[®] NCCN Guidelines™ Version 2.2011 Gastric Cancer

❖ Post-op Volumes:
uniform CTVs Prescription !!

❖ **MD methodology for postop CT changes !!!!!**

EORTC guidelines



Radiotherapy and Oncology 92 (2009) 164–175
Contents lists available at ScienceDirect
Radiotherapy and Oncology
journal homepage: www.thegreenjournal.com

Guidelines
EORTC-ROG expert opinion: Radiotherapy volume and treatment guidelines for neoadjuvant radiation of adenocarcinomas of the gastroesophageal junction and the stomach
Oscar Matzinger ^{a,b,c}, Erich Gerber ^c, Zvi Bernstein ^d, Philippe Maingon ^e, Karin Haustermans ^f, Jean François Bosset ^g, Akos Gulyban ^h, Philip Poortmans ^h, Laurence Collette ^g, Abraham Kuten ^d

❖ Preop Volumes:

❖ OARs contouring: accurate !!

❖ Clinical Outcome